

Septoplasty with trans-septal suturing versus merocel packing (A comparative study)

Hazem M. Abdel Tawab, Hatem S. Badran

Department of Otorhinolaryngology, Faculty of
Medicine, Cairo University, Egypt

Correspondence to Hazem M. Abdel Tawab
Tel: 01110579379
e-mail: hazemabdeltawwab77@yahoo.com

Received 30 August 2014

Accepted 27 September 2014
PAN Arab Journal of Rhinology
2015, 1:33-37

Background: nasal packing after septoplasty is usually done for hemostasis

Objective: to compare between septoplasty with trans- septal suturing and septoplasty with merocel packing

Patients and methods: eighty eight patients with deviated nasal septum causing persistent nasal obstruction were included in the study. They were randomly divided into two equal groups; group A included patients where septoplasty with trans- septal suturing was done while group B patients had septoplasty with merocel packing. Comparison was done regards surgical time, post-operative pain, bleeding, hematoma, synechia formation and septal perforation

Results: significant difference (p value < 0.00001) between group A and group B was noticed as regards surgical time and post-operative pain while both groups showed no difference regarding incidence of hematoma, synechia or septal perforation. There was no significant difference between both groups as regards post-operative bleeding

Conclusion: Trans- septal suturing is a good alternative to nasal packing after septoplasty that offers shorter surgical time, less pain and more comfort for the patient post operatively.

Keywords: septoplasty, hematoma, nasal packing

INTRODUCTION

Septoplasty is one of the commonest surgical procedures done to relieve nasal obstruction, either alone or in combination with inferior turbinectomy. Post septoplasty nasal packing is usually used for hemostasis and as an internal support but it can be used also to prevent hematoma, infection and septal perforation. [1]

Reviewing the literature ; surgeons are using nasal packs which differ in the used materials like Vaseline gauze, glove fingers, gel foam, surgical and merocel packs with antibiotics on. [2] Some complications may arise from nasal packs due to the fact of lymphatic and venous obstruction caused by them such as mucosal insult, septal perforation, and respiratory distress during sleep, [3] pain, [4] need for hospitalization, [5] decreased arterial oxygen saturation during sleep, [6] allergy and Eustachian tube dysfunction. [7] The use of nasal packs is usually associated with discomfort and pain and its removal mostly leads to bleeding and pain. Use of post septoplasty nasal packs is considered a controversy. Aim of this study is to compare between cases of septoplasty with merocel packing versus with trans- septal suturing.

PATIENTS AND METHODS

This prospective randomized study was done on eighty eight patients who underwent septoplasty due to persistent nasal obstruction. The study was conducted on patients admitted in the Otorhinolaryngology Department, Faculty of Medicine, Cairo University from June 2012 till October 2013. Patients were randomly divided into two equal groups by drawing a paper with the name of the group from a box; Group A which included 44 patients underwent septoplasty with trans-septal suturing technique while group B which with the same number of patients underwent septoplasty with merocel packing.

Exclusion criteria

- 1- Allergic patients
- 2- Hypertrophied inferior turbinates by endoscopy or computed tomography (CT) scan
- 3- Patients with sinusitis or DM

4- Patients with coagulation defects

Informed consent was taken from every patient after discussing the nature of the operation.

All the patients were subjected to thorough history taking stressing on onset, course and duration of nasal obstruction and response to antihistamines and if they received any form of corticosteroid medication to exclude allergy. Anterior rhinoscopy and endoscopic examination were done to confirm the diagnosis of deviated nasal septum and exclude nasal turbinate hypertrophy and signs of infection or allergy. All the patients were subjected to preoperative full laboratory tests. Patients were operated by one surgeon.

Surgical techniques

All patients were operated under general anesthesia. Local infiltration of the mucosa of the nasal septum with 2ml xylocaine on saline epinephrine 1: 200,000 was done to control any possible bleeding. Killian incision was done for all cases. The deflected cartilage parts were

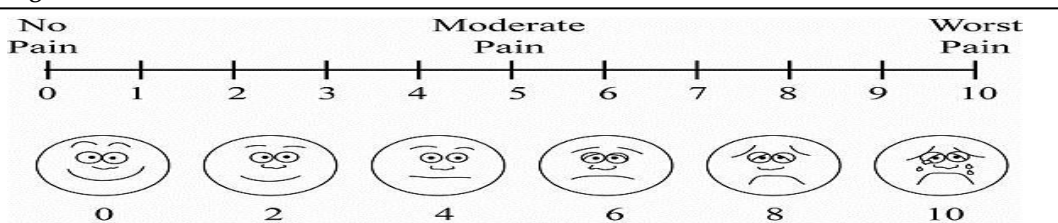
removed, straightened and repositioned. All the incisions were sutured with 4-0 vicryl.

In Group A, simple transfixion sutures were done using 4-0 vicryl after repositioning of the straightened cartilage by a needle holder. The sutures started from the posterior part to make the mucoperichondrial flaps more stable, while in group B merocel packing was inserted and after 48 hours it was removed.

Both groups received amoxicillin clavulanic acid 1.2 gm intravenously every 12 hours for the two days of admission then after discharge they were given amoxicillin clavulanic acid 1 gm tablet/ every 12 hours for five days, nasal saline for irrigation and analgesic when needed.

Patients were instructed to record their pain and discomfort levels in the first two days after operation using a visual analogue score (figure 1) of 10 grades where grade 0 is no pain and grade 10 is maximal worst pain.

Figure 1



Pain visual analogue score used in the study

Patients were compared regarding the surgical time of both techniques.

Post operatively they were followed for pain, bleeding regardless the amount, septal hematoma, adhesions and septal perforation.

Patients were followed in the initial 48 hours, then seen after one week and after one month from the surgery.

Data collection and statistical analysis

Data were entered on the computer using "Microsoft Office Excel Software" program (2010) for windows. Data was then transferred to the Statistical Package of Social Science Software program, version 21 (SPSS) to be statistically analyzed.

Mean and standard deviation were calculated for quantitative variables and percentage for qualitative ones. Comparison between groups was performed using independent sample t-test for quantitative variables and Chi square or Fissure exact test for qualitative ones.

Paired t-test was conducted to signify the changes. P values less than 0.05 were considered statistically significant, and less than 0.01 were considered highly significant.

RESULTS

This prospective study was done on eighty eight patients with deviated nasal septum complaining from nasal obstruction in the period from June 2012 till October 2013. Patients were admitted in the Department of Otorhinolaryngology, Faculty of Medicine, Cairo University. They were randomly divided into two equal groups; group A included 44 patients where septoplasty with trans- septal suturing was done and group B also included 44 patients where septoplasty with merocel packing was done. In group A, there were 29 males (65.91%) and 15 females (34.09%). Age of patients in this group ranged from 21-45 years with mean of 31.795 and standard deviation (SD) of 5.869. In group B, there were also 29 males (65.91%) and 15 females (34.09%). Age of patients in this group ranged from 24-46 years with mean of 35.659 and SD of 5.425.

As regards the surgical time consumed in each technique starting after completion of general anesthesia till the end of the surgical work, group A mean surgical time was about 35 minutes while group B

mean surgical time was about 44 minutes giving a highly significant p- value of <0.00001. Table 1 shows some statistical tests regarding the surgical time in both groups.

Table 1 Statistical analysis of surgical time between the two groups

Surgical time in minutes	Group A	Group B
Mean	35.02272727	44.43181818
Variance	13.32505285	7.14384778
Observations	44	44
Pooled Variance	10.36945032	
Hypothesized mean difference	0	
DF	86	
T Stat	-13.70506619	
P (T<=t) one-tail	1.12298E-23	
T critical one-tail	1.662765449	
P (T<=t) two-tail	2.42596E-23	
T critical two-tail	1.987934206	

As regards post-operative pain using the visual analogue score, patients in group A have a mean pain score of 3.36 while patients in group B have a mean pain

score of 6.22. Again this result gives a highly significant p- value of <0.00001. Table 2 shows statistical analysis of mean pain score in the two groups.

Table 2 Statistical analysis of mean pain score in both groups

	Group A	Group B
Mean	3.363636364	6.227272727
Variance	0.422832981	0.505285412
Observations	44	44
Pooled Variance		0.464059197
Hypothesized mean difference		0
DF		86
T Stat		19.7170763
P (T<=t) one-tail		5.88347E-34
T critical one-tail		1.662765449
P (T<=t) two-tail		1.17669E-33
T critical two-tail		1.987934206

Results regarding septal hematoma, septal synechia and septal perforation in the two groups are shown in Table 3.

Table 3. Results regarding septal hematoma, synechia and perforation in the two groups

	Number of cases in group A	Number of cases in group B
Septal hematoma	0	0
Septal synechia	2	2
Septal perforation	1	1

As regards post-operative bleeding in the two days of admission; Group A showed 7 cases (six males and one female) while group B showed 5 cases (4 males and one female). This gives a non-significant p value of 0.539.

DISCUSSION

Septoplasty is one of the commonest surgical methods used for correction of septal deviation. [9] Post-operative nasal packing has been used for approximation of mucoperichondrial flaps, hemostasis and prevention of septal haematoma. Also it was used to prevent synechia between the septum and lateral nasal wall. [5] Due to the fact that nasal packing can lead to complications as pain, [4] difficult breathing and defective oxygenation [10] and infection [11] some studies were presented to assess the need for nasal packing after septoplasty.

In this study, comparison between septoplasty with trans- septal suturing and with merocel packing revealed that suturing takes significantly less surgical time than with merocel packing. Post-operative pain in this study was significantly less in patients with trans-septal suturing than in patients with merocel packing. This matches with the results of Bajaj et al., in 2009 [12] and Cukurova et al., in 2012. [8]

Regarding post-operative bleeding, it was more in trans- septal suturing group than in merocel packing group but without significant difference.

In Basavaraj et al., study published in 2011, [13] on 151 patients they found that bleeding was much more in the first two days after surgery in cases without packing than in septoplasty with packing however, in the third day no bleeding occurred in the no- packing group compared to the other group with significant difference.

Cukurova et al., study published in 2012 [8] documented that bleeding was more in the packing group than the suture group but without significant difference.

As regards the incidence of septal perforation there was no difference in this study and this match with the study of Awan and Iqbal in 2008. [14] Also, Basavaraj et al study in 2011 [13] found no significant difference between septoplasty with and without packing.

In Cukurova et al., study, [8] the incidence of septal perforation in the group with trans- septal suturing was 8 (2.2%), whereas in the group with nasal packing, 11 (3.2%) cases were observed. Significant differences were not found between the two groups with respect to the formation of septal perforation.

In this study, no cases of septal hematoma occurred in both groups. Also there was no significant difference between both groups as regards septal synechia which happened in two patients in each group.

In Cukurova et al. study, [8] seven patients in the group with trans- septal suturing and five patients in the group with nasal packing developed nasal synechia giving no significant difference between both groups. According to Lemmens and Lemkens study [5] in 2001 on 226 cases of septal suturing, they reported no complications as bleeding, hematoma or perforation. Al-Raggad et al., study in 2007 [15] coincided with this study s regards the less incidence of complications of trans- septal suturing after septoplasty.

CONCLUSION

Trans- septal nasal suturing is a good alternative to nasal packing after septoplasty. It offers shorter surgical time and much less pain with very small rate of complications as bleeding, hematoma, synechia and septal perforation. This study confirms that routine nasal packing after septoplasty is no more needed or justified as trans- septal suturing offers much more comfort for the patients.

Conflicts of Interest

There were no conflicts of interest

REFERENCES

1. Erkhan G, Ergin NT. Comparison of suture and nasal packing in rabbit noses. *Laryngoscope*. 2004;144:639-45.
2. Daneshrad P, Chin Gregory Y, Rice Dale H. Fibrin glue presents complications of septal surgery: Findings in a series of 100 patients. *Ear Nose and Throat Journal*. 2003;82:196-8.
3. Jensen PF, Kristensen S, Johannesen NW. Episodic nocturnal hypoxia and nasal packs. *Clin Otolaryngol*. 1991;16:433-5.

4. Yilmazer C, Sener M, Yilmaz I, et al. Pre-emptive analgesia for removal of nasal packing: A double-blind placebo controlled study. *Auris Nasus Larynx*. 2007;34:471-5.
5. Lemmens W, Lemkens P. Septal suturing following nasal septoplasty, a valid alternative for nasal packing? *Acta Otorhinolaryngol Belg*. 2001;3:215-21.
6. Yigit O, Cinar U, Uslu B, et al. The effect of nasal packing with and without an airway on arterial blood gases. *Kullak Burun Bogas Ihtis Derg*. 2002;9:347-50.
7. Thompson AC, Crowther JA. Effect of nasal packing on Eustachian tube function. *J Laryngol Otol*. 1991;105:539-40.
8. Cukurova I, Cetinkaya EA, Mercan GC, et al. Retrospective analysis of 697 septoplasty surgery cases: packing versus trans-septal suturing method. *Acta Otorhinolaryngol Ital*. 2012;32:111-4.
9. Sedwick JD, Lopez AB, Gajerwski BJ, et al. Caudal septoplasty for treatment of septal deviation: Aesthetic and functional correction of the nasal base. *Arch Facial Plast Surg*. 2005;7:158-62.
10. Yiğit O, Cinar U, Uslu B, et al. The effect of nasal packing with or without an airway on arterial blood gases. *Kulak Burun Bogaz Ihtis Derg*. 2002;9:347-50.
11. Fairbanks DN. Complications of nasal packing. *Otolaryngol Head Neck Surg*. 1986;94:412-5.
12. Bajaj Y, Kanatas AN, Carr S, et al. Is nasal packing really required after septoplasty? *Int J Clin Pract*. 2009;63:757-9.
13. Basavaraj N, Walikar SM, Rashinkar MV, et al. A Comparative Study of Septoplasty with or without nasal packing. *Indian J Otolaryngol Head Neck Surg*. 2011;63:247-8.
14. Awan MS, Iqbal M. Nasal packing after septoplasty; a randomized comparison of packing versus no packing in 88 patients. *J Ear Nose Throat*. 2008;87:624-7.
15. Al-Raggad DK, El-Jundi AM, Al-Momani OS, et al. Suturing of nasal septum after septoplasty, is it an effective alternative to nasal packing? *Saudi Med J*. 2007;28:1534-6.