

## Closed Septorhinoplasty: A Middle East Experience

Mohammed Tawalbeh,<sup>a</sup> Saadallah M. Alzacko,<sup>b</sup> Basil M.N. Saeed<sup>c</sup>

<sup>a</sup> ENT Department Jordan University Hospital,  
<sup>b</sup> Plastic Surgery Department, College of Medicine,  
Mosul University, <sup>c</sup> Department of Surgery,  
College of Medicine, Mosul University, Iraq

Correspondence to Mohammed Tawalbeh  
Tel: 00962795598959  
e-mail: mtawalbeh@yahoo.com

Received 2 August 2014  
Accepted 15 December 2014  
PAN Arab Journal of Rhinology  
2015, 1:2-13

**Introduction:** Septorhinoplasty/ or rhinoplasty has traditionally been being performed by the otorhinolaryngologists for functional disorders or for external deformity, and by the general plastic surgeons for cosmetic indications. The goal of rhinoplasty is to fashion a natural nose that is in harmony with its surrounding facial features.

**Objectives:** The aim of this study is to outline the procedure of closed rhinoplasty / or septorhinoplasty in our geographic locality in the middle east. The patients' demographics, the indications of surgery, the procedure adopted in surgeries and the outcome were assessed with some details.

**Patients and Methods:** It is a retrospective study in which patients that underwent closed septorhinoplasty or rhinoplasty alone in the period from 2007-2011 were studied and their charts were reviewed. They were recruited from 2 centers in the middle east, the first is Jordan University Hospital/ Amman/ Jordan, and the second is Mosul teaching and private hospital/ Mosul/ Iraq.

**Results:** The study included 560 patients, their ages ranged from 17-56 with mean of (23.26) years. There were 230 males (41%) and 330 females (59%) and the follow up period ranged from 1-3 years. The majority of patients (520) (93%) had septorhinoplasty, only 40 patients (7%) had rhinoplasty alone. The paper discusses the operative technique, and the outcome.

**Conclusion:** The endonasal approach in rhinoplasty is quite satisfactory in the middle east with good outcome.

**Keywords:** Septorhinoplasty, Rhinoplasty, Closed, Endonasal

### INTRODUCTION

Septorhinoplasty/ or rhinoplasty has traditionally been being performed by the otorhinolaryngologists, for functional disorders or for external deformity correction following trauma, and by the general plastic surgeons as well as the otolaryngologists for cosmetic indications. The goal of the surgery is to fashion a natural nose that is in harmony with its surrounding facial features. This includes alteration of anatomically normal but unappealing nasal appearance, posttraumatic deformities, and congenital anomalies. [1,2] Cosmetic deformities can be classified into nasal pyramid problems and nasal tip problems. The over projected nasal dorsum or dorsal hump is the most common reason patients present for cosmetic alteration of nontraumatic nose. [3] A second indication for rhinoplasty is to improve nasal breathing. The septorhinoplasty is indicated for nasal obstruction when the deformity is such that correction of the dorsal deformity is necessary to straighten the septum. [4]

Most corrections of the long nose associated with a hump or dorsal deformities follow the basic principles

formulated by Jacques Joseph in the first half of the 20th century. [5,6]

There are two approaches in rhinoplasty, the closed or endonasal approach and the open or external approach. By the end of the 20th century it became apparent that the pendulum had swung too far in favor of the external approach and that most patients would benefit from endonasal surgery. [7,8]

The classic Joseph rhinoplasty is performed through intercartilagenous and full length transfixion incision and consists of: hump reduction, lowering of the cartilaginous dorsum, triangular shortening of the caudal edge of the nasal septum, lateral osteotomies with infraction and alar cartilage cephalic rim excision. [7,9,10]

The aim of the present study is to evaluate 560 patients who underwent closed septorhinoplasty, or rhinoplasty in 2 centers in the Middle East, including patients' demographics, indications of surgery, the adopted surgical technique and the outcome of surgery. It is an overview of a large sample of patients which is

representative to population residing in the Middle East.

**PATIENTS AND METHODS**

It is a retrospective study in which patients who underwent closed septorhinoplasty or rhinoplasty alone in the period from 2007-2011 were studied and their charts were reviewed. Surgeries were performed in 2 centers in the Middle East. These centers are: Jordan University Hospital/ Amman/ Jordan, and Mosul Teaching and private hospitals/ Mosul/ Iraq. The patients' ages ranged from 17- 56 with mean of (23.26) years. There was (230) males and (330) females and the follow up period ranged from 1-3 years. All patients had preoperative photographs in the following positions: frontal, basal, right and left lateral, and right and left oblique.

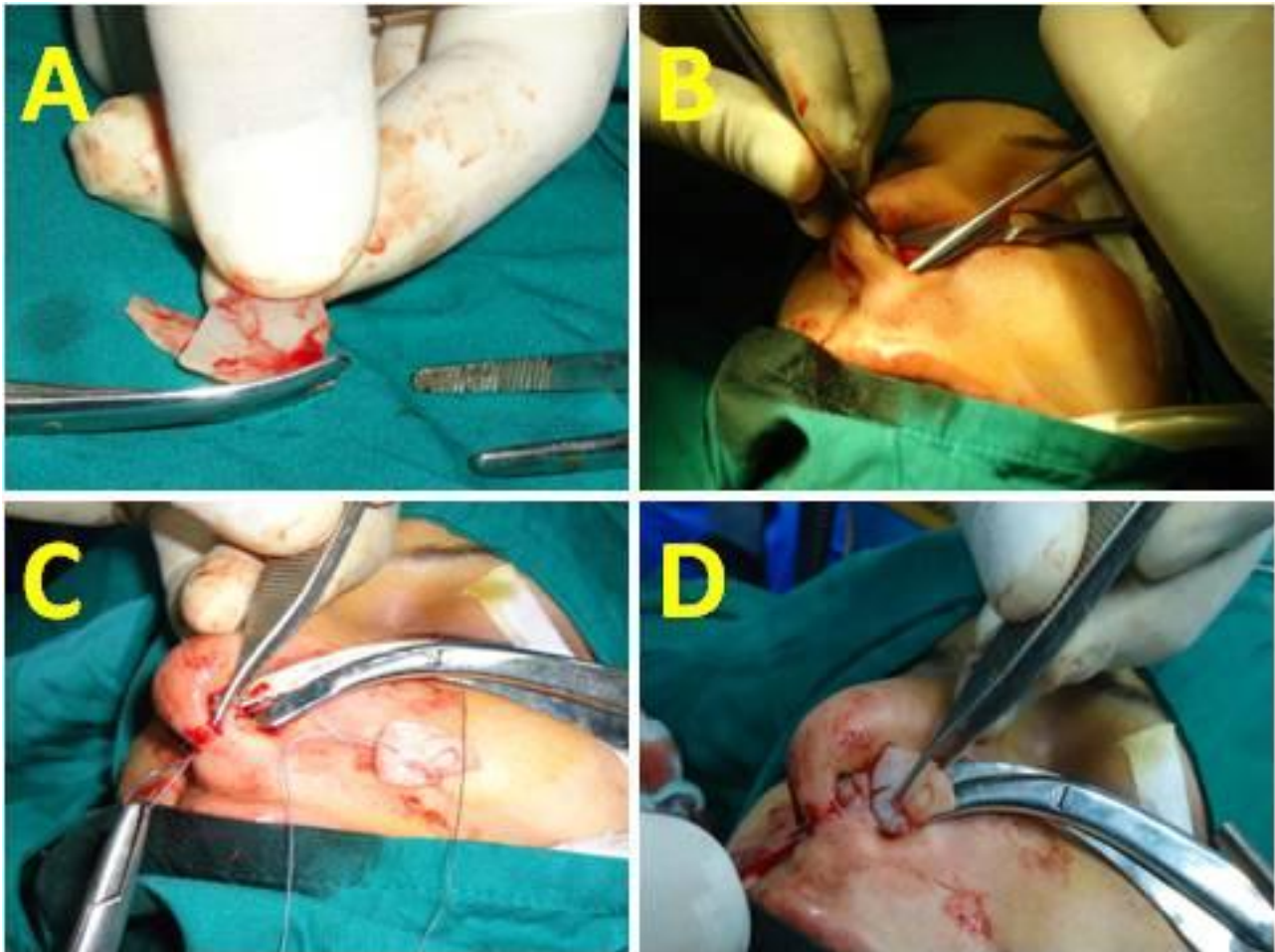
The majority of patients (520) had septorhinoplasty, only (40) had rhinoplasty alone.

**The surgical procedure:**

All patients had the surgery done under general endotracheal anaesthesia with supine position and 30 degrees head elevation.

**Septoplasty:** the aims of septoplasty are first; a conservative resection of the septal cartilage, reinsertion of the regular pieces of excised cartilage into the septum and reconstruction of the caudal septum and columella. Sometimes it needed removal of a big piece or the whole of septal cartilage, re-fashioned and inserted as a free graft into a tunnel in the columella and fixing the graft in place by mattress suture (Fig.1).

**Figure 1**



**a** Septal cartilage preparation, **b** dissection of columellar tunnel. **c & d** insertion of the cartilage into the pocket

After completion of septoplasty, the hemitansfixion incision was partially closed using single 3/0 vicryl in the posterior half of the incision. Intranasal silastic

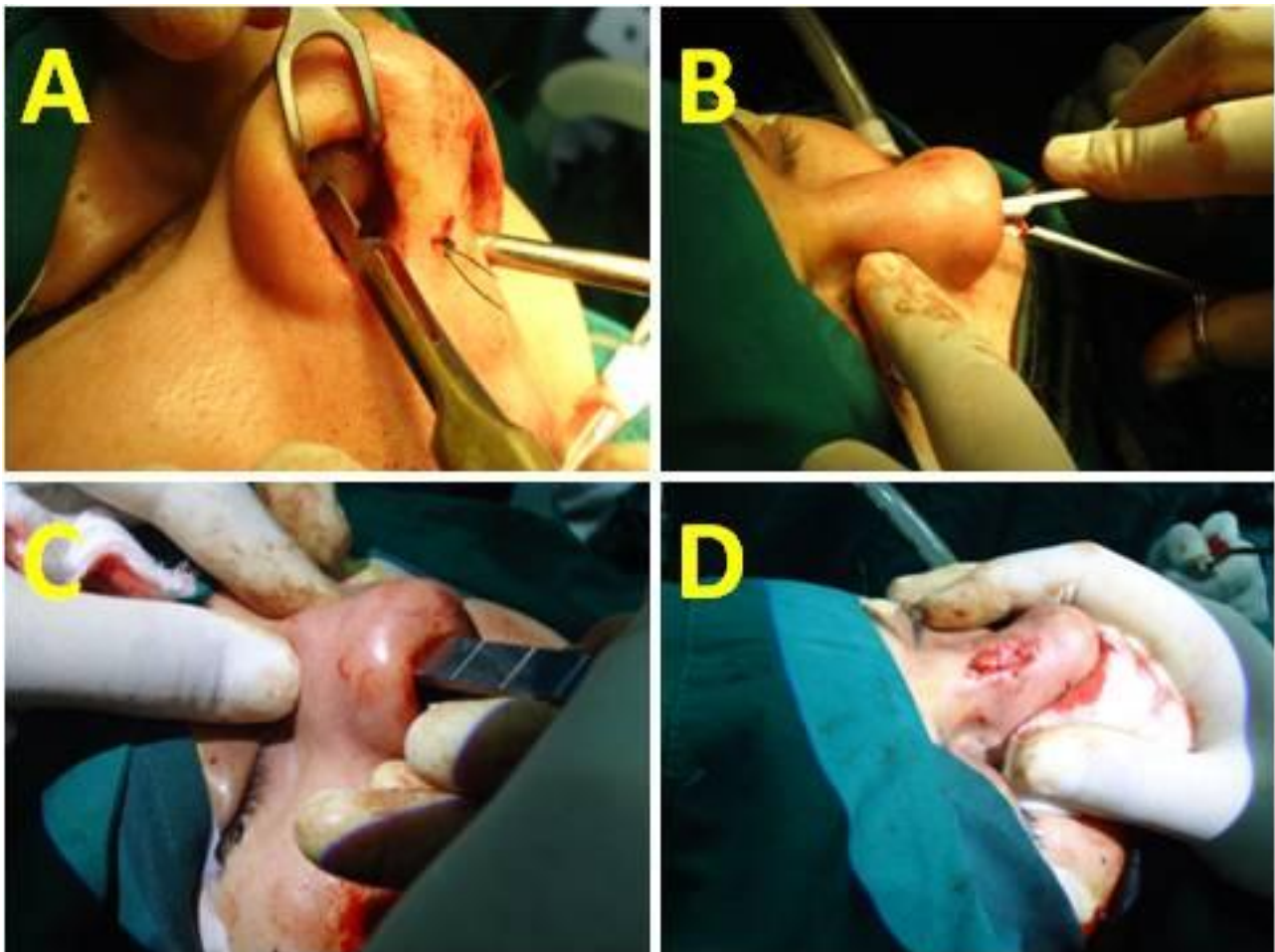
splints were inserted and suture fixed assuring that the anterior edge of the silastic was situated behind the site of hemi or transfixion incisions.

**Rhinoplasty** was then commenced with bilateral intercartilagenous incisions and transfixion incision which extends to less than the columellar half length. (Fig. 2). In approximately half of patients who underwent cephalic excision of the LLC, a

transcartilagenous incision was done instead of intercartilagenous incision.

The next step was hump removal, which was done in the majority of cases as in block excision using a 10 mm osteotome. (Fig. 2).

**Figure 2**

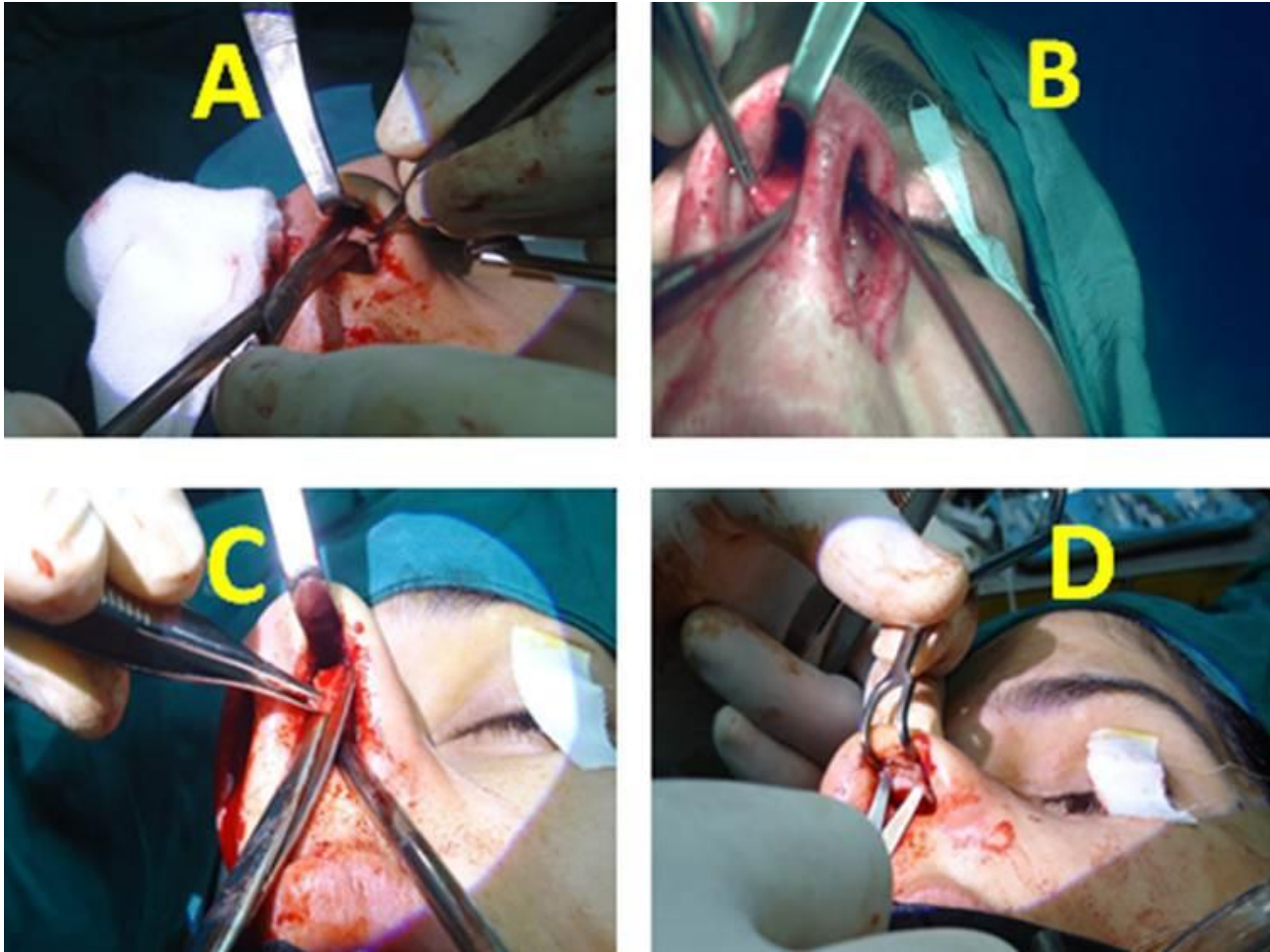


Steps of rhinoplasty, **a** intercartilagenous incision, **b** elevation of musculo-aponeurotic layer, **c,d** hump removal by 10 mm osteotome

Hump removal was followed by rasping of the bony dorsum to smooth the bony edges. In the majority of patients the upper lateral cartilages were separated from the septum using an elevator or a scissor keeping their mucosal attachment intact. The medial edge of the ULC

was lowered to be at the same level with the bony nasal dorsum. A triangular piece of the lower medial edge of ULC might need excision to prevent its protrusion into the nasal vestibule (Fig. 3).

Figure 3

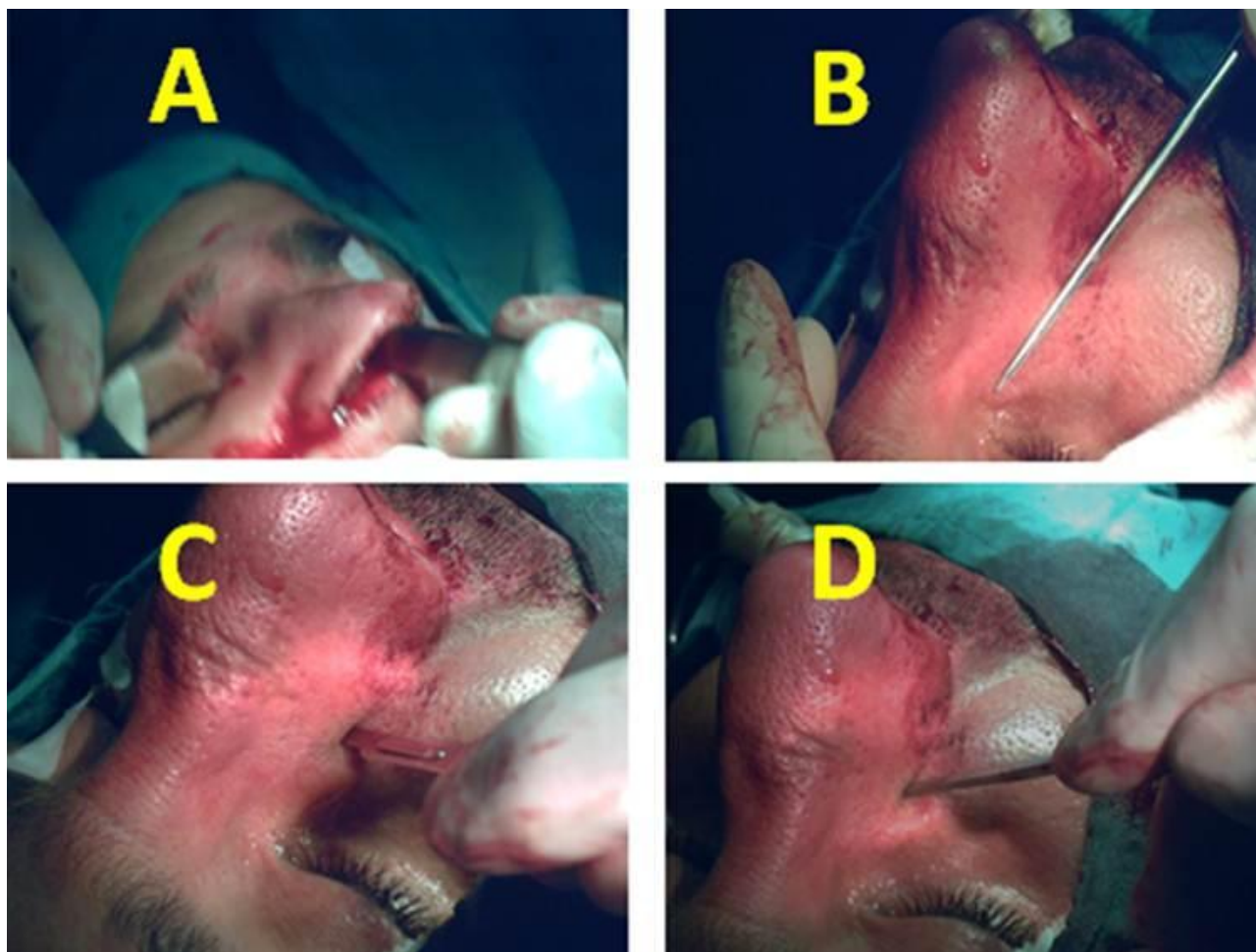


a & b separation of the ULC from the septum, c lowering and trimming of the ULC, d cephalic excision of the LLC

The following step was bilateral medial osteotomies using a 10 mm osteotome which was inserted between the nasal septum and the nasal bone. Just below the intercanthal line, it is angulated 30 degrees laterally and a dehiscence was created in the anterosuperior part with the aid of a hammer (Fig. 4).

The next step was bilateral lateral osteotomies either external osteotomies using a 2 mm osteotome, or internal osteotomies using a curved guarded 4 mm osteotome. In our series, intermediate osteotomies were done only in severely deviated noses.

Figure 4



a medial osteotomy, b,c,d lateral osteotomies

**For bulbous tip**, the only procedure done was cephalic excision of a strip of the lower lateral cartilage, and this was done either by transcartilagenous approach or cartilage delivery approach. (Fig. 3). When excessive alar flaring was present, alar base excision might be required, and the wound was closed using 6/0 nylon suture.

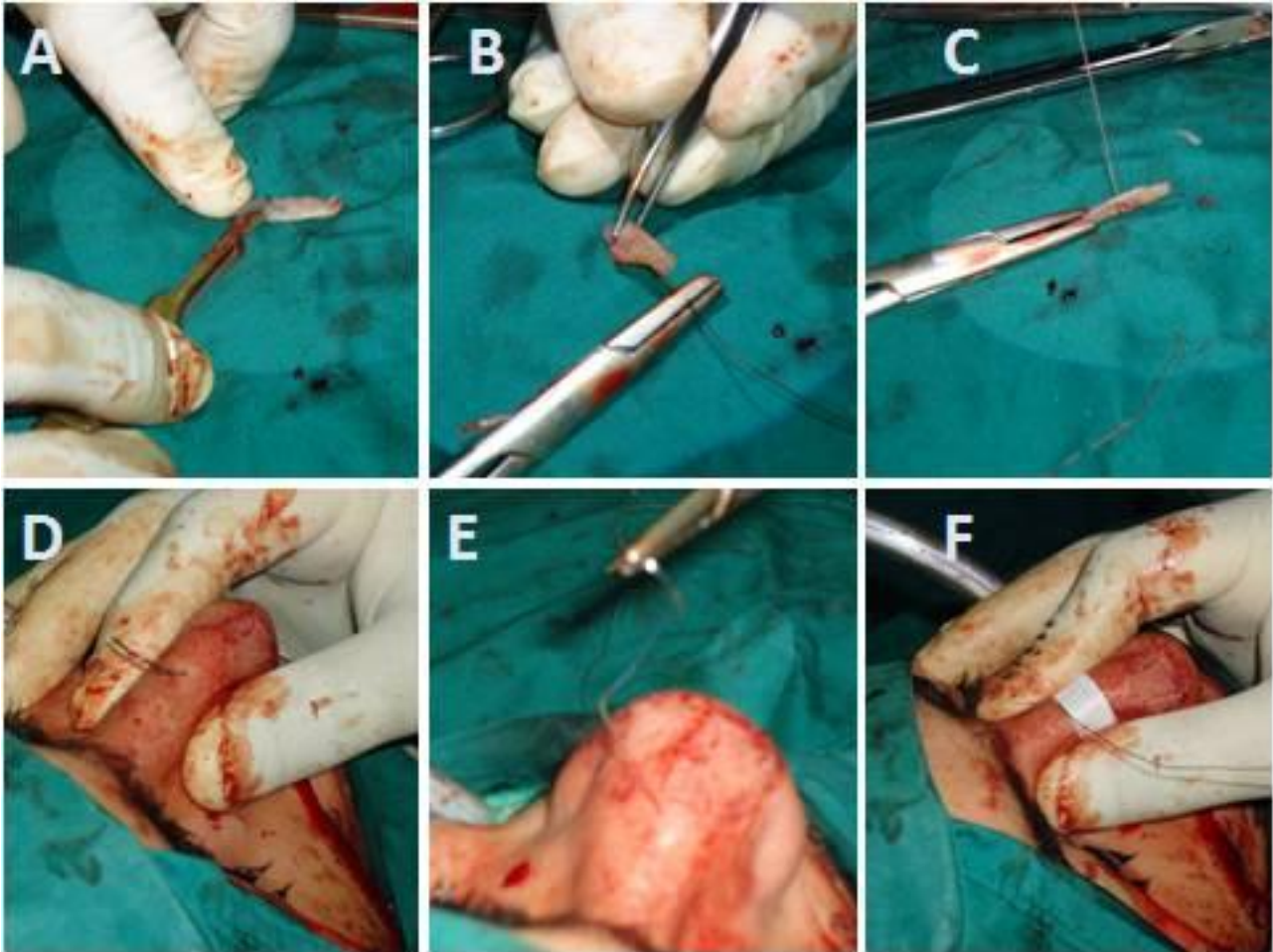
Assessment of the profile was needed to find any irregularity or supratip depression. In such case a dorsal cartilaginous graft was inserted. The graft is taken either from the septal cartilage or from the excised alar cartilage. A vicryl 3/0 was passed into the graft, and the free end of the suture is knotted behind the graft. The needle is passed from inside to outside holding the graft which is positioned in the desired place. The suture is cut about 2 cm from the skin and it is taped to the skin (Fig.5).

Packing of the nasal cavities with vaseline packs was followed by firm application of adhesive tapes over the external nose. External nasal splints (8-10 layers of Plaster of Paris) was fashioned in the shape of half

moon, applied to the dorsum and held firmly until it dried and then taped to the skin. Broad spectrum antibiotics were given for 10 days, especially when grafts are used. The external nasal splints as well as the intranasal silastics were usually removed one week after the surgery. Sutures of the dorsal grafts were cut flush with the skin at the time of splint removal, while the sutures of alar base excision were left to be removed 3 days later. The patient is seen one week later to make assessment of the results of surgery and the first postoperative photos were taken. The next assessment was done a month later. The second postoperative photos were usually taken 6 months after surgery, by that time decisions of revision surgery may be taken.

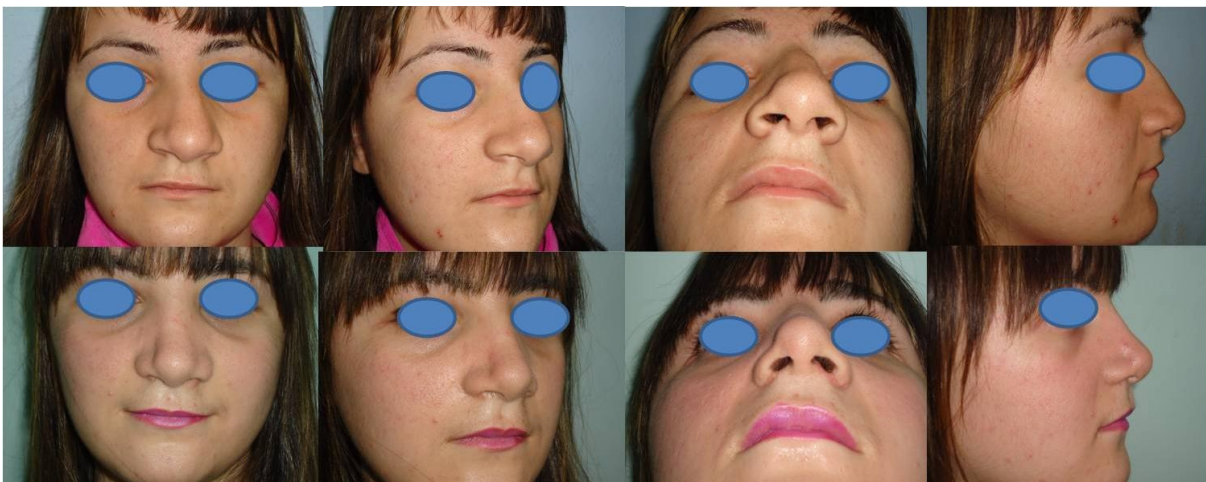Follow up period were about 1-3 years, and in each visit, a good time was spent on listening to the patients notes about the nose shape, complaints of nasal block and if needed detailed examination including endoscopy may be needed. Investigations like CT scan of paranasal sinuses were requested if there is suspicion of sinusitis.

Figure 5



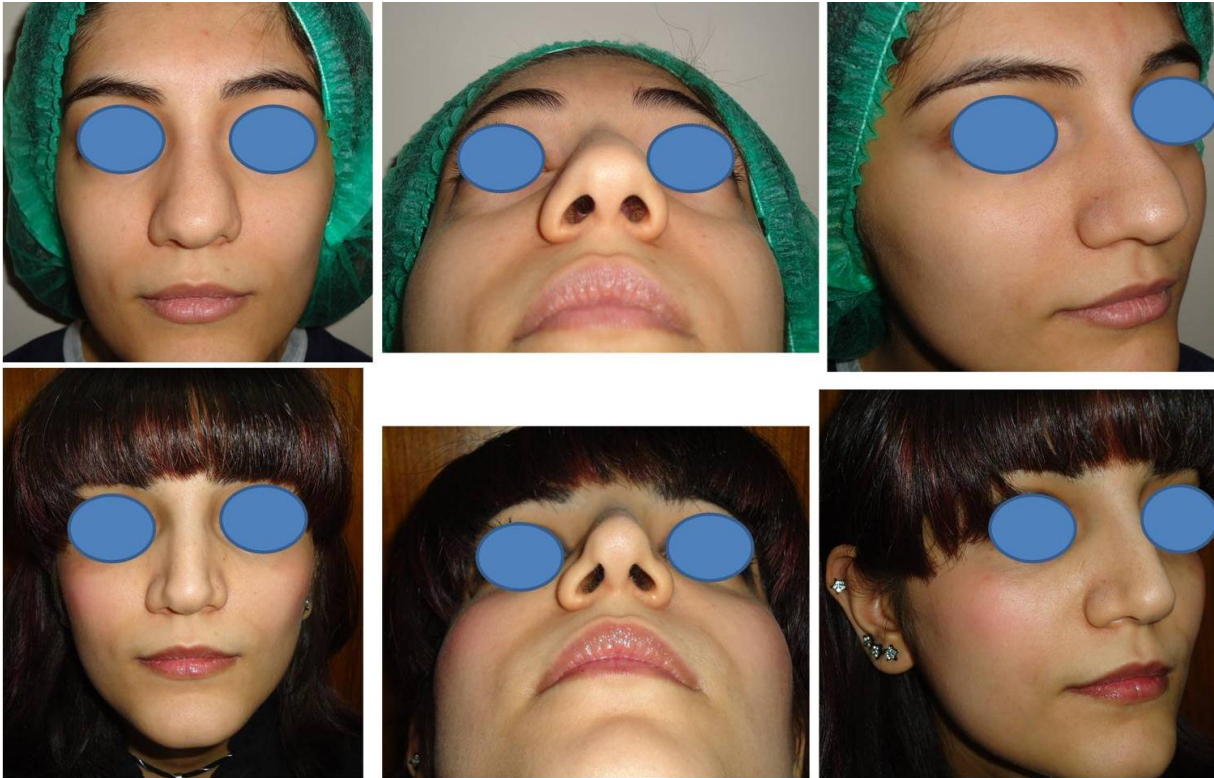Dorsal graft taken from the septal cartilage, **a** fashioned by the knife, **b,c** the needle is passed through the cartilage and its free end knotted behind the cartilage, **d,e** the needle is passed from inside to outside at the dorsum, **f** taping the free end on the skin

Figure 6



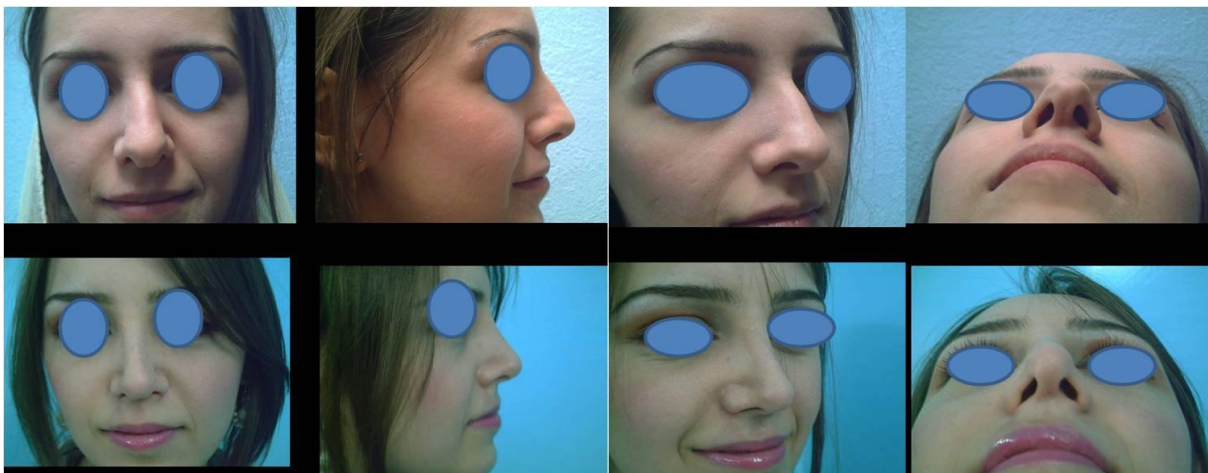
Preoperative (the above row), and postoperative (lower row) photos of a patient who had septorhinoplasty, hump removal, straightening of deviated dorsum, cephalic excision of LLC, and alar base narrowing

Figure 7



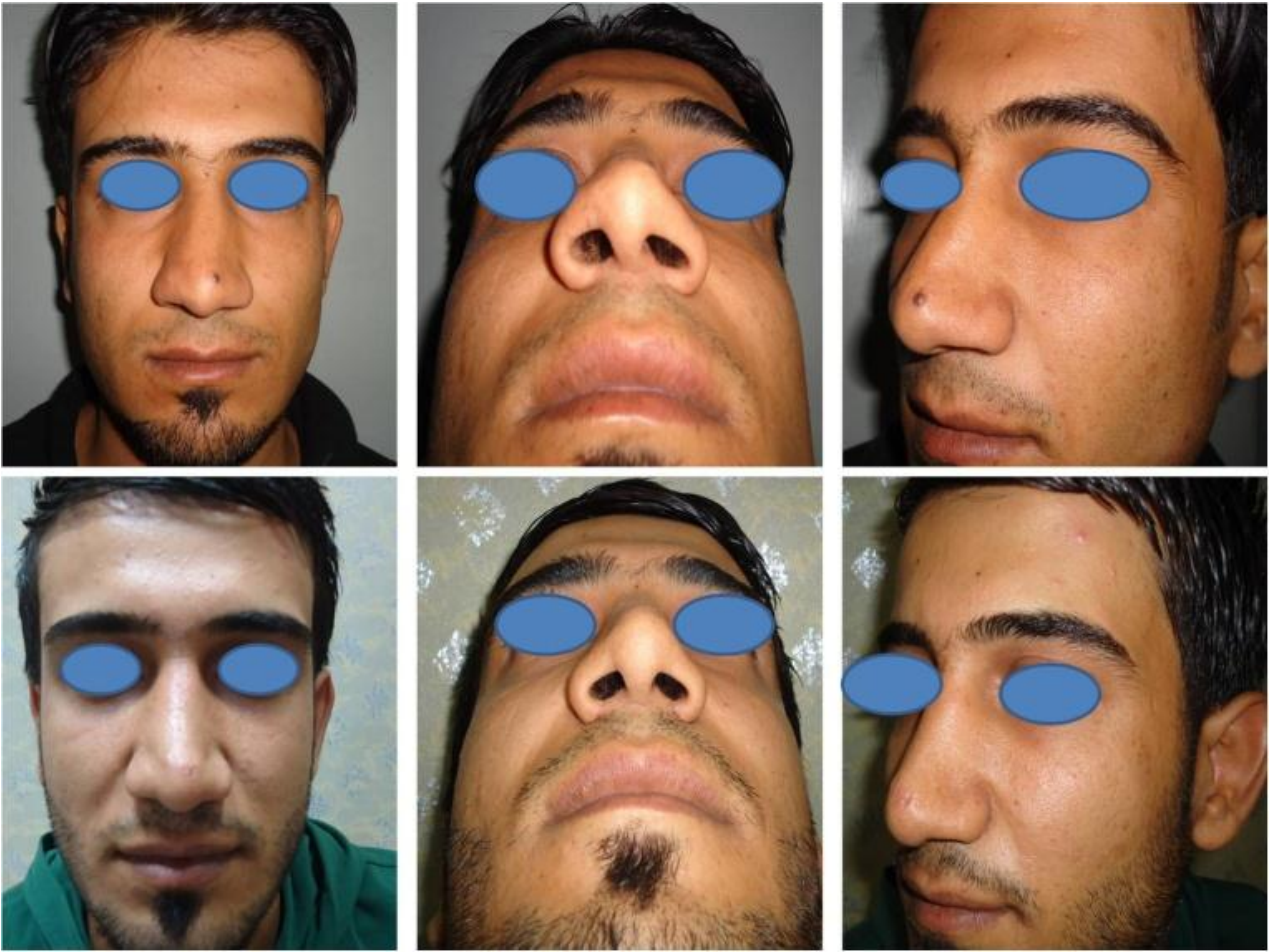Preoperative (above), postoperative (below) photos of a patient, she had revision septoplasty with cartilage insertion into a columellar pocket, humpectomy, correction of external deviation and cephalic excision of LLC

Figure 8



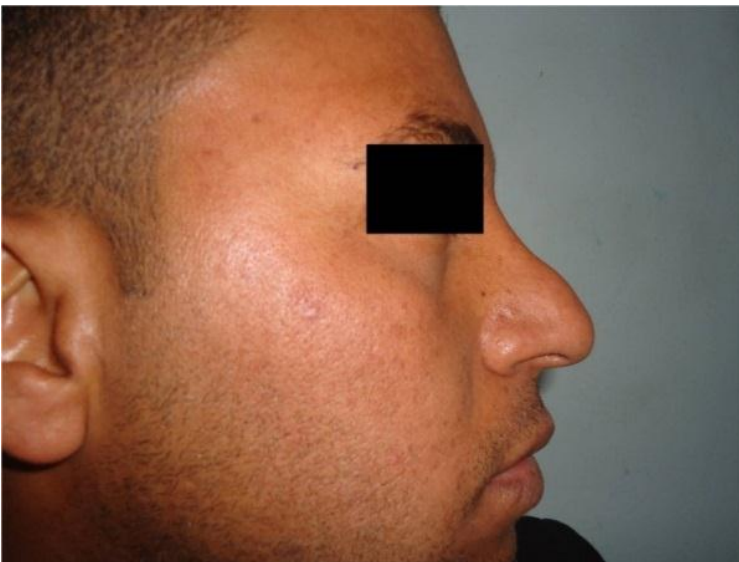
Preoperative (above), postoperative (below) photos of a patient who had septorhinoplasty: hump removal, straightening of deviated dorsum and cephalic excision of LLC

Figure 9



Alar base excision for alar flaring, preoperative (above), and the postoperative (below)

Figure 10



pollybeak deformity after rhinoplasty

## RESULTS

Rhinoplasty was performed by closed (endonasal approach) in 560 patients over a four years period. There were {230(41%)} males, and {330(59%)} females. The age range was from (17-56) with mean of (23.26) years. In 40 patients (7.14%)rhinoplasty was done without concomitant septal surgery because either the septum is not deviated or it has been previously operated on. The series included mainly primary surgeries in 545(97%), and revision surgeries were only 15 cases. In patients who had septoplasty, 22 patients (3.9%) had revision surgeries and in 53 patients (9.46%) there was a need for cartilage removal and reinsertion in the columella. Table I demonstrates the demographics of patients and the surgical procedures.

**Table I Demographics of patients with septorhinoplasty**

Females	330 (59%)
Males	230 (41%)
Age	17-56, mean 23,26 years
Primary surgery	545(97%)
Revision	15 (3%)
Septorhinoplasty	520 (93%)
Revision septoplasty	22(3.9%)
Rhinoplasty alone	40 (7%)
30 pts: no DNS, 10 pts: previous septoplasty	

**Abbreviations:** DNS: deviated nasal septum

The cosmetic problems were manifested with humps and/or dorsal deviations without tip problem or with minimal tip bulbosity. In some patients there was alar flaring as well.

**Table II The functional and cosmetic problems**

Septal cartilage reinserted in a columellar pocket	53 (9.5%)
Humps	520 (93%)
Bony dorsal deviation	274 (49%) (Some with Cart. Dev)
Intermediate osteotomies	40 (7%)
Cartilaginous dorsal deviation	184 (33%) (Some with bony deviation)
Dorsal grafts needed	61 (11%)
Tip bulbosity	168 (30%) cephalic excision of LLC
100 (18% delivery approach), 68 (12% transcartilagenous approach)	61 (11%) alar base reduction

**Abbreviations:** Cart. Dev.: cartilage deviation

**Table III Functional results and complications**

Postoperative nasal block	68 (12.14%)
51 patients (9.1%)improved on medical treatment	
7 patients(1.2%) needed SMD	
10 patients(1.8%) needed revision septoplasty	
4 pts: septoplasty alone	
6 pt :septoplasty+ SMD	

**Abbreviations:** pt: patient, SMD: submucus diathermy

Dorsal humps were present in 520 patients (93%). Bony dorsal deviation was present in 274 patients (49%) with or without humps. Cartilaginous deviation was present in about 184(33.3%) patients, and this can be alone or associated with bony deviation. Intermediate osteotomies were done in severely deviated noses and was needed in 40 patients (7%). Tip bulbosity was present in about 168 patients (30%) and they underwent cephalic excision of the LLC. (Fig. 7,8, 9). In approximately 100 patients (18%), it was done by delivery approach, while in the rest 68 patients (12%) it was done by transcartilagenous approach. Alar base reduction was done in 61 patients (11%) with excessive alar flaring (Figs. 7,10). Table II demonstrates the functional and cosmetic problems of the patients.

During the course of surgery, supratip saddle mainly followed hump excision because of excessive removal of its cartilaginous component, and this was treated with dorsal cartilaginous graft in 61 patients (11%) (Fig. 6).

The success of surgery was assessed by first, achieving good airway and relief of nasal block, and second by the patient satisfaction with the new nose shape.

In 68 patients (12.12%) there was postoperative nasal block and they were assessed for other concomitant problems like allergic or non-allergic rhinitis and were given treatment for this reason. Fifty-one patients (9%) had improvement in their nasal breathing. Residual septal deviation was found in 10 patients (1.8%). Revision septoplasty was needed to improve the nasal breathing with or without submucus diathermy in those patients. In 7 patients (1.2%) submucosal diathermy alone was needed for improving the nasal breathing (Table III).

There is no rhinomanometry facility in our centers so the assessment was done based on clinical grounds.

Regarding the cosmetic results, it has been found that the degree of satisfaction is increased when the patient views his own photos comparing the preoperative with his postoperative results. The patient is usually supplied with a CD containing the photos in a form of comparison between the preoperative and the postoperative ones (Figs. 6-9).

In our series, revision rhinoplasty was done in about 66 patients (11.78%). Residual humps and dorsal irregularities were present in 23 patients (4.1%), and pollybeak deformity in 10 patients (1.78%) (Fig.10). Deviation in the cartilaginous part was present in 18 patients (1.8%), while deviation in the bony dorsum was found in 10 patients (1.78%). In 5 patients (0.9%), supratip saddle was present.

In all but 3 patients, the revision surgery solved the cosmetic problems. One female patient with residual hump needed a second revision for residual dorsal irregularity, while in 2 patients open rhinoplasty procedure was done after the first closed revision. Patients with cartilaginous deviation underwent revision septoplasty with removal of the septal cartilage and reinserting it as a free graft in a tunnel in the columella, and it was enough for correction of the deviation, while in those with bony deviation

osteotomies were needed for correction. The patient with supratip saddle underwent revision septal work to get a cartilage graft which was applied as a dorsal graft and this was sometimes preceded by rasping of the bony dorsum to get the acceptable profile alignment.

In 30 patients (5.3%), the results were unappealing to the authors. In 13 patients there was residual deviation in the bony dorsum, in 13 patients residual humps were present, and slight cartilaginous deviations were present in 4 patients. Those patients were satisfied with the nose shape and did not request revision surgery.

Epistaxis occurred in one patient about 2 weeks after surgery, and on endoscopic examination, a bony spicule was found in the posterior flap causing injury to the mucosa and bleeding stopped when this bone piece was removed. Intranasal adhesions were found in 10 patients and those were opened under local anesthesia.

**Table IV Unaccepted cosmetic results**

Residual dorsal humps or irregularity	36 pts(6.4%), 23 pts(4.1%) had revision surgery
Pollybeak deformity	10 patients(1.8%) underwent revision
Cartilaginous dorsal deviation	22 patients(4%) : 18 revision septoplasty
Bony dorsal deviation	23 patients (4.1%): 10 revision and osteotomies
Supratip saddle	5 patient(0.9%): revision surgery

**DISCUSSION**

Rhinoplasty is perhaps the most challenging and complex procedure in facial plastic surgery. Classically rhinoplasty consists of the following interrelated steps: septoplasty, tip surgery, hump removal, narrowing of the nose with osteotomies and final correction of subtle deformities.

It seems from patients' demographics that male rhinoplasty accounts for 41%, which could be explained on post-traumatic reasons. [7,9,10]

In our series, the intercartilagenous approach is used for dorsal deformity or hump. The main tip procedure was cephalic excision of the LLC. Patients who needed major tip work had external rhinoplasty approach and were not included in the study.

Because most of our patients were candidates for reduction rhinoplasty (93%), even mild degree of septal deviation which did not cause nasal block, were considered for septoplasty to avoid postoperative nasal block. [11] Besides, this reflects the nature of the Middle East noses with humps as the main indication for rhinoplasty.

Regarding hump excision, it can be removed in block, or it can be removed in stages, the cartilaginous hump first and then the bony part. If the hump is small, it can be

remove by shaving with a knife or a rasp. [12] In our series, all these maneuvers were applied accordingly.

Regarding the ULC, there is great concern about leaving a mucosal contact with the septum to avoid nasal valve collapse. [13,14]

Operative textbooks describe the division of ULC from the septum and their reduction in a way that they are at the same level of the nasal septum and nasal bones. Some studies advocated partial resection of the ULC to reduce the width of middle third of the nose. [15-18] In our series, in the majority of cases the ULC was separated from the nasal septum with excision of a triangular piece from its lower medial edge of ULC. The majority of patients did not have nasal block, and in addition it adds the benefit of avoiding the pollybeak deformity which usually results from under resection of the ULC and the septum. Otherwise in patients in whom the middle third was already narrow, such resection was kept to minimum to avoid postoperative nasal valve collapse. [17,19,20] Also in deviated cartilaginous dorsum, separation of the ULC from the septum is needed to get the septum straightened and positioned in the midline.

In more than half of the series, lateral osteotomies were done by external approach using a 2 mm osteotome. Tardy and Denney helped popularize the use of micro-osteotome to more precisely perform osteotomies as

well as to minimize the damage to both the supportive periosteum and the intranasal mucosa. [21]

The lateral osteotomy has received attention because of the many challenges this maneuver presents. The perforating technique has been noted to provide better preservation of the periosteal attachments laterally. [22]

Dorsal grafts were needed in about (11%) of patients, and these grafts were taken from the nasal septal cartilage, or from the excised alar cartilage. These grafts were sculptured and suture fixed to the overlying skin.

The literature is replete with articles that illustrate minimal absorption of autogenous cartilage in long-term follow up, and the graft maintains its pre-grafted architecture. [23-26] In an endonasal rhinoplasty approach, a precise pocket is usually created to house the graft. The skilled rhinoplasty surgeon relies on an exact fit and external splinting to prevent graft migration. [27]

In our series there were very satisfying results with the dorsal graft regarding the cosmetic outcome and the graft viability.

Regarding the cephalic excision of the LLC, the main procedure in one center (Jordan) was by the delivery approach, while it was by the transcartilagenous approach in the other center (Iraq). It had no much impact on the results, it might reflect the adopted procedure.

Alar base reduction is an integral part of rhinoplasty, and is considered when the interalar distance exceeds the intercanthal distance. The goals of the wedge excision are to avoid over straightening the ala, to preserve the natural curvature of the ala, and to avoid telltale incisions into the nostril opening. The relative indication for sill reduction is when the nostril is enlarged and has a horizontal axis. [28]

Wedge excision of the alae was practiced in the operated patients, and this was associated with still excision in about half of cases (Figs. 7,10).

Approximately 10-20 % of patients undergoing primary rhinoplasty are dissatisfied with the result of surgery and request revision.4 The deformities being dealt with in revision surgery can be divided into upper third, middle third, and lower third deformity. Deformities can be in the form of pollybeak, saddling, midnasal asymmetry and retracted columella. [29]

In our series 66 patients (11.78%) required revision surgeries for: residual humps in (4.1%), pollybeak deformity in (1.78%), bony deviation in (1.78%), cartilaginous deviation in (1.8%), and saddle nose in (0.9%). In addition the results in 30 (5.3%) patients were not ideal for the authors, and those patients might be

candidates for revision surgery, yet they did not request it, so making the unacceptable results 17%. Revision surgery improved the outcome in the operated patients.

Endonasal rhinoplasty approach can deliver fantastic results while minimizing procedural time, intraoperative bruising, and swelling, and leaving significant cartilaginous native attachments in place. In reality, most patients do not seek to undergo major structural changes in their nose. Furthermore, even the most complex nasal deformities can be approached endonasally, with the supplement of grafting and suturing procedures. [30-33]

## CONCLUSION

The endonasal technique provides an excellent alternative to the more radical external approach. The endonasal technique is an adequate method of dealing with even the most complex of cases. The authors think that this approach is more practical in the Middle East noses as the shape of the Arabic nose with hump which is candidate to reduction rhinoplasty that is easily achieved by the closed approach. Besides, our population was found to accept the less dramatic shape change with the natural looking nose after closed approach.

## REFERENCES

1. Rees TD, LaTrenta GS. *Aesthetic Plastic Surgery*, 2nd ed. Philadelphia: WB Saunders, 1994.
2. Tardy ME. *Rhinoplasty: the Art and the Science*. Philadelphia: WB Saunders; 1997.
3. Tardy ME. *Rhinoplasty*. Baltimore, Williams & Wilkins, 1984.
4. Marks SC. *Nasal and Sinus surgery*. Philadelphia: WB Saunders, 2000.
5. Behrbohm H, Briedigkeit W, Kaschke O. Jacques Joseph: Father of Modern Facial Plastic Surgery. *Arch Facial Plast Surg*. 2008;10:300-3.
6. Triana R. Jacques Joseph: Surgical Sculptor. *Arch Facial Plast Surg*. 1999; 1:324-5.
7. Toriumi DM, Becker DG. *Rhinoplasty Dissection Manual*. Philadelphia, PA: Lippincott Williams & Wilkins, 1999.
8. Palma P, Khodaei I. Hybrid Rhinoplasty: The 21st Century Approach to Remodeling the Nose. *Arch Facial Plast Surg*. 2010;12:412-14.
9. Sheen JH, Sheen A. *Aesthetic Rhinoplasty*. 2nd ed. St. Louis: CV Mosby; 1987.
10. Byrd HS, Hobar PC. Rhinoplasty: a practical guide for surgical planning. *Plast Reconstr Surg* 1993; 91: 642-54, discussion 655-6.

11. Bull TR, Mackay IS. Rhinoplasty. In Scott-Browns Otolaryngology (Rhinology) 6th ed. Butterworth-Heinemann. Oxford. 1997.
12. Jones NS. Rhinoplasty and Septorhinoplasty, in Bleach N, Milford C & Hasselt AV, Operative Otorhinolaryngology. Blackwell Science Ltd. Oxford. 1997.
13. Torium DM. Management of the middle nasal vault. Operative Tech Plast Reconstr Surg. 1995; 2:16-30.
14. Khosh MM, Albert J, Honrado C, Pearlman SJ. Nasal valve reconstruction: experience in 53 consecutive patients. Arch Facial Plast Surg. 2004;6:167-71.
15. Filho ACNN, Sass SMG, Marcelino TF. Elliptic Excision of the Upper Lateral Cartilage in the Rhinoplasty for Correction of the Large Middle Third. Int. Arch. Otorhinolaryngol. 2009; 13:304-8.
16. Prendiville S, Zimble MS, Kokoska MS, Thomas J. Middle-Vault Narrowing in the Wide Nasal Dorsum: The "Reverse Spreader" Technique. Arch Facial Plast Surg. 2002;4:52-5.
17. Thomas JR, Prendiville S. Overly Wide Cartilagenous Middle Vault. Facial Plast Surg Clin North Am. 2004;12:107-10.
18. Sachs ME. Mastering Revision Rhinoplasty. New York: Springer, 2006.
19. Holt GR, Garner ET, McLarey D. Postoperative sequelae and complications of rhinoplasty. Otolaryngol Clin North Am. 1987;20:853-76.
20. Parkes ML, Kanodia R, Machida BK. Revision rhinoplasty: an analysis of aesthetic deformities. Arch Otolaryngol Head Neck Surg. 1992;118:695-701.
21. Tardy ME, Denney JC. Micro-osteotomies in rhinoplasty. Facial Plast Surg. 1984;1:137-45.
22. Murakami C, Larrabee W. Comparison of osteotomy techniques in the treatment of nasal fractures. Facial Plast Surg. 1992;8:209-19.
23. Stucker FJ, Hoasjoe DK. Nasal reconstruction with conchal cartilage. Arch Otolaryngol Head Neck Surg. 1994;120:653-8.
24. Daniel RK. Rhinoplasty: a simplified, three-stitch, open tip suture technique, part II: secondary rhinoplasty. Plast Reconstr Surg. 1999;103:1503-12.
25. Park C, Kim ES, Roh TS. Needle fixation technique in cartilage grafting. Ann Plast Surg. 1999;43:331-3.
26. Stephenson AJ, Brotherston TM. Technique of percutaneous anchoring suture replacement. Plast Reconstr Surg. 1999;104:1442-3.
27. Tardy ME, Toriumi DM. Philosophy and principles of rhinoplasty. In: Papell D, Nachlas N, eds. Facial Plastic and Reconstructive Surgery. St Louis, Mo: Mosby. 1992:278-94.
28. Kridel RH, Castellano RD. A Simplified Approach to Alar Base Reduction: A Review of 124 Patients Over 20 Years. Arch Facial Plast Surg. 2005;7:81-93.
29. Vuyk HD, Watts SJ, Vindayak B. Revision rhinoplasty: review of deformities, aetiology and treatment strategies. Clin Otolaryngol Allied Sci. 2000;25:476-81.
30. Tasman AJ, Palma P. The infracartilaginous approach revisited. Arch Facial Plast Surg. 2008;10:370-5.
31. Kamer FM, McQuown SA. Revision rhinoplasty. Analysis and treatment. Arch Otolaryngol Head Neck Surg. 1988;114:257-66.
32. Bagal AA, Adamson PA. Revision rhinoplasty. Facial Plast Surg. 2002;18:233-44.
33. Dayan S, Kanodia R. Has the pendulum swung too far? Trends in the teaching of endonasal rhinoplasty. Arch Facial Plast Surg. 2009;11:414-16.