



Choanal Adenoid after Conventional Curettage Adenoidectomy

Reda H. Kamel, Ahmed F. Abdel Fattah

Department of Otorhinolaryngology, Faculty of Medicine, Cairo University

Correspondence to: Reda H. Kamel, Email: rhinology@redakamel.com

Background: *Remnant of adenoidal tissue is a common sequel of conventional curettage adenoidectomy. Choanal remnant is one of the causes of persistent symptoms.*

Aim of Work: *To report the incidence of choanal remnants after curettage adenoidectomy, and to verify their exact site of origin.*

Methods: *102 children aged between 3 and 12 years with primary adenoid hypertrophy (62 males and 40 females) were subjected to surgical removal of the adenoids by curettage. The endoscope was utilized to assess any remnant/s, and their site/s, with a special concern to choanal remnants.*

Results: *Adenoidal remnants were detected in 94 patients (92.2%). Twenty-four patients (23.5%) presented with choanal remnants; 6 patients had true origin from the choana, while the remaining 18 patients had an origin from the roof of the nasopharynx.*

Conclusion: *Adenoid residual is a common finding after blind curettage adenoidectomy. Remnants discovered at the choana are not always truly choanal in origin.*

Keywords: *Choanal adenoid, Conventional adenoidectomy, Curettage, Adenoidal remnants, Residual, Recurrence.*

INTRODUCTION

The relationship between the hypertrophied adenoids and the choana is of utmost importance. When adenoidal hypertrophy during childhood fills the nasopharynx and reaches the choana, upper airway obstruction will be noticed. Sequelae include mouth breathing, rhinorrhea, sleep-disordered breathing.^(1,2) Adenoid obstruction may also lead to an open anterior bite and "adenoid facies" secondary to chronic oral breathing. Pulmonary hypertension, and secondary right-side cardiac hypertrophy have been reported in severe cases.^(3,4)

The size of the adenoid tissue, its relation with choanal opening and nasopharyngeal obstruction degree comprise

some of the important factors in determining the candidates for adenoidectomy.⁽⁵⁾

Although various techniques have been described, the "blind technique" is still widely performed.⁽⁶⁾ Blind curettage cannot clear the adenoidal tissue within the posterior choana, which is sometimes the most important cause of recurrence. The residual tissue at the pharyngeal roof near choanal openings might result in obstructive symptoms.⁽⁷⁾ Thus new techniques have been suggested for adenoidectomy utilizing nasal endoscopy, electrocautery, lasers, and microdebriders.^(8,9)

Although adenoid residuals after conventional adenoidectomy have been comprehensively well studied

Choanal Adenoid after Conventional Curettage Adenoidectomy

including choanal adenoid, to our knowledge, the origin of choanal adenoid remnants has never been directly addressed. The purpose of this study was to report the incidence of choanal adenoid remnants after conventional curettage adenoidectomy, and to verify their exact site of origin.

PATIENTS AND METHODS

This prospective study was done between July 2011 and January 2013. One hundred and two patients with primary adenoidal hypertrophy were included (62 males and 40 females). Age of the patients ranged between 3 and 12 years. Patients presented to the outpatient clinic complaining of chronic nasal obstruction, persistent nasal discharge, and/ or snoring. Some patients had recurrent throat pain, fever and/ or deafness. Adenoid hypertrophy was diagnosed by nasal endoscopy where all the patients showed bilateral choanal blockage by adenoid tissue. Informed consent was taken from the parents. Patients with previous adenoidectomy, submucous cleft palate, severe septal deviation, nasal polypi, or nasal tumours were excluded from the study.

Patients were subjected to removal of the adenoids by curettage. Some had additional tonsillectomy, myringotomy, and/ or ventilation tubes insertion.

Surgery was done under general anaesthesia using orotracheal intubation. Curettage of the adenoids was followed by dissection of any remnants using the index finger to ensure complete removal, with subsequent nasopharyngeal packing for 10 minutes. After removal of the pack, the 30 degree 4 mm Storz® rigid endoscope was introduced bilaterally below the inferior nasal turbinate towards the nasopharynx without changing the position of the patient. An accurate endoscopic evaluation of the adenoidal bed was carried out to exclude any adenoidal remnant. Special care was directed to the remnants at the choana, posterior nasopharyngeal wall, vault, fossa of Rosenmuller, posterior lip of Eustachian tube and/or naso-oropharyngeal junction.

Evaluation of the outcome after surgery was reported in the form of presence or absence of adenoidal remnants, and site /s of attachment.

RESULTS

The study group (102 patients) included 62 males (60.8%), and 40 females (39.2%). Their ages ranged between 3 and 12 years, with a mean \pm standard deviation (mean \pm SD) of 5.69 \pm 2.279 years. Eighty five patients had additional tonsillectomy (83.3%), 17 had bilateral myringotomy and grommet's tubes insertion (16.7 %), and 3 had unilateral grommet 's (2.9%). Endoscopic examination of the

nasopharynx at the end of the surgery revealed presence of adenoidal remnants in 94 patients (92.2%).

The incidence of remnants at different attachments sites is presented in Table 1.

Table 1. Incidence of remnants at different sites.

Site	Number, percentage
1- Posterior wall of nasopharynx	61 (59.8%)
2- Roof of nasopharynx	78 (76.5%)
3- Fossa of rosenmuller	2 (2%)
4- Junction oro&nasopharynx	42 (41.2%)
5- Choana	6 (5.9%)
6- Eustachian tube orifice	2 (2%)
7- Posterior lip eustachian tube	24 (23.5%)

Choanal obliteration was identified in 24 patients (23.5%); remnants at the choana proper in 6 patients (25%), and at the roof of nasopharynx with extension into the choana in 18 patients (75%). Bilateral choanal obliteration was observed in 4 patients; one (25%) with an origin in the choana proper, and 3 (75%) at the roof of the nasopharynx (3/ 18) (Fig. 1).

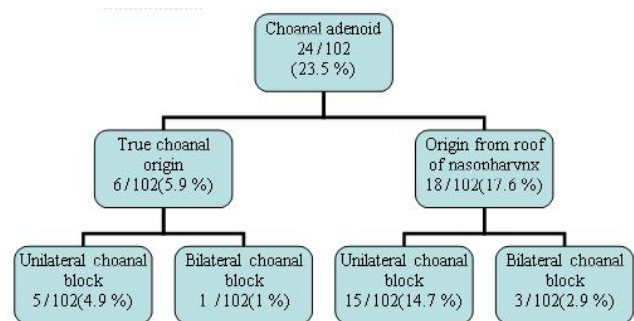


Fig 1. Origin of choanal adenoid remnants.

DISCUSSION

Choanal adenoid is a well-known, widely used term to describe adenoid tissue extending from the nasopharynx into the choanae and posterior nasal cavity.^(10,11) The relation of the adenoid tissue with choanal opening comprises an important factor in determining patients with symptoms and candidates for adenoidectomy.⁽⁵⁾ Many of the previous studies have considered the incidence and locations of adenoid residuals including choanal remnants after conventional curettage adenoidectomy, but none had related choanal remnants to

the exact origin and attachment sites. In the current study, special concern was directed to identify incidence of choanal residual after curettage adenoidectomy and trace it to its site of origin.

Curettage has yielded excellent results and was the standard technique for adenoidectomy until the late 20th century.⁽¹²⁾ The approach to the nasopharynx was indirect, and as the adenoids are lymphatic vegetations without discrete borders, it is more difficult to completely remove them.⁽¹³⁾ The main disadvantage of curettage is that a relatively a blind technique that may skim the adenoidal bulk, leaving behind obstructing tissue, particularly at the Eustachian tube orifices, high in the nasopharynx, and at the choana.⁽⁹⁾ Adenoidal remnants and regrowth are the most common cause for recurrence and or persistence of symptoms. The efficacy of conventional adenoidectomy in completely removing adenoidal tissue ranges between 30% and 61% in previous studies.^(14,2) In the present study, remnants were observed intraoperatively using nasal endoscopy in 92.15% of the patients.

Ark et al., reported that the pharyngeal roof near choanal openings is the most frequent localization for residual adenoid tissue (87.3%) and every surgeon should visualize this localization for a remnant before completion of the surgery.⁽¹⁵⁾ In this work, the most common site of remnant s was also the roof of the nasopharynx, 78 cases (76.5%), only 18 cases (17.6%) have reached the choana.

Interestingly, choanal remnants were identified in 24 102 patients (23.5%) in the current study; only 6 patients had true origin from the choana (25%), while the remaining 18 patients had origin from the roof of the nasopharynx (75%). On the contrary, other authors had reported that choanal adenoidal remnant did not emerge from the rhinopharynx but from the roof of the choanae, the posterior part of the nasal septum and in some cases also from the lateral wall of the choanae.^(11,16)

Blind curettage cannot clear the adenoidal tissue within the posterior choana, which is also difficult to visualise by the mirror, thus resulting in missing adenoid tissue. This is the most important cause of recurrence of adenoids, and persistent airway obstruction.^(6,10,11,17,16) Not all adenoidal remnants were expected to cause symptoms, the critical size for adenoids to cause symptoms is when they fill more than 50% of the posterior choanae.^(18,19)

It is worthy to mention that choanal remnants were unilateral in 20 cases (19.6%), and bilateral in 4 cases (3.9%). These remnants may account for immediate postoperative persistent symptoms. On the other hand, one should not forget the remnants at other locations namely; the posterior wall of the nasopharynx in 61 patients (59.8%), the roof of the nasopharynx in 78 patients (76.5%), the fossa of rosenmuller in 2 patients

(2%), the junction between oropharynx and nasopharynx in 42 patients (41.2 %), the eustachian tube orifice in 2 patients (2%), and in the posterior rim of Eustachian tube in 24 patients (23.5%). These remnants may account for adenoid regrowth and delayed recurrence of symptoms.

It seems that identification of the adenoid residuals, and localization of the site of attachment and their relation to the choana helps complete removal with lower incidence of recurrent symptoms.

CONCLUSION

Intraoperative visualisation of the nasopharynx after curettage adenoidectomy, especially when the endoscope is utilized, helps to demonstrate site of origin of any missed adenoid tissue.

Although choanal remnants are encountered in some cases, remnants truly originating from the choana are not common (5.9%).

REFERENCES

1. Thornval A, Wilhem Meyer and the adenoids. Arch Otolaryngol Head Neck Surg. 1969;90:383-5.
2. Havas T, Lowinger D. Obstructive adenoid tissue, Arch Otolaryngol Head Neck Surg. 2002;128:789-92.
3. Strong B, Rubinstein B, Senders CW. Pathologic analysis of routine tonsillectomy and adenoidectomy specimens. Orolaryngol Head Neck Surg. 2001;473-7.
4. Bravo G, Ysunza A, Arrieta J, Pamplona M. Videonasopharyngoscopy is useful for identifying children with Pierre Robin sequence and severe obstructive apnea, Int J Pediatr Otorhinolaryngol. 2005;69:27-33.
5. Caylakli F, Hizal E, Yilmaz I, Yilmazer C. Correlation between adenoid–nasopharynx ratio and endoscopic examination of adenoid hypertrophy: A blind, prospective clinical study. Int J Pediatr Otol. 2009;73:1532–5.
6. Ezzat WF. Role of endoscopic nasal examination in reduction of nasopharyngeal adenoid recurrence rates. Int J Pediatr Otol. 2010;4:404–40.
7. Buchinsky FJ, Lowry MA, Isaacson G. Do adenoids regrow after excision? Otolaryngol. Head Neck Surg. 2000;123:576–81
8. Huang HM, Chao MC, Chen YL, Hsiao HR. A combined method of conventional and endoscopic adenoidectomy. Laryngoscope. 1998;108:1104-6.
9. Koltai PJ, Kalathia AS, Stanislaw P, Heras HA. Power-assisted adenoidectomy. Arch Otolaryngol. Head Neck Surg. 1997;123:685-8.

Choanal Adenoid after Conventional Curettage Adenoidectomy

10. Clemens J, McMurray S, Willging P. Electrocautery versus curette adenoidectomy: comparison of postoperative results. *Int. J Paediatr Otol.* 1998;43:115-22.
11. Orntoft I, Bonding P. Choanal adenoid syndrome--a preliminary report. *Acta Otolaryngol.* 2000;543:220-1.
12. Shapiro NL, Bhattacharyya N. Cold dissection versus coblation-assisted adenotonsillectomy in children. *Laryngoscope.* 2007;117:406-10.
13. Joushua B, Bahar G, Sulkes J, Shpitzer T, Raveh E, Tikva P. Adenoidectomy: long-term follow-up. *Otolaryngol Head Neck Surg.* 2006;135:576-80.
14. Bross-Soriano D, Schimelmitz-Idi J, Arrieta-Gomez JR. Endoscopic adenoidectomy; use or abuse of technology? *Cirugia y cirujanos.* 2004;72:1-19.
15. Ark N, Kurtaran H, Ugur KS, Yilmaz T, Ozboduroglu AA, Mutlu C. Comparison of adenoidectomy methods: Examining with digital palpation vs. visualizing the placement of the curette. *Int J Pediatr Otol.* 2010;74:649-51.
16. Orntoft I, Bonding P. Ectopic adenoid tissue in the choanae. *J Laryngol Otol.* 2001;115:198-201.
17. Timms MS, Ghosh S, Roper A. Adenoidectomy with the coblator: a logical extension of radiofrequency tonsillectomy. *J Laryngol Otol.* 2005;119:398-9.
18. Wormald PJ, Prescott CA. Adenoids: comparison of radiological assessment methods with clinical and endoscopic findings. *J Laryngol Otol.* 1992;106:342-4.
19. Elwany S. The adenoidal-nasopharyngeal ratio (AN ratio). Its validity in selecting children for adenoidectomy. *J Laryngol Otol.* 1987;101:569-73.