

Nasolabial cyst: Case Report

Jihan A. Al Maddah

ORL, H&NS, Prince Sultan Military Medical City, Riyadh, Saudi Arabia

Email: jihanalmaddah@hotmail.com

Nasolabial cyst is a relatively uncommon benign extraosseous maxillary lesion. They are thought to arise from remnants of the nasolacrimal ducts, most of the available information is limited to case reports and case series by mostly maxillofacial surgeons.

This type of cyst is approached differently by sublabial complete excision or endoscopic nasal marsupialization.

This case is presented because uncommon lesion presented to Rhinologist and approached by endoscopic intranasal excision with the use of the debridor with short hospital stay and no recurrence for more than a year.

Keywords: Nasolabial, cyst, sublabial excision, endoscopic marsupialization.

INTRODUCTION

Nasolabial cyst is a non-odontogenic, slowly growing characterized by its extraosseous location below the nasal ala and the medial nasal fold. Less common older names for this lesion include klestadt cyst, nasal vestibule cyst, nasal wing cyst, and mucoid cyst of the nose.⁽¹⁾

The first documentation of Nasolabial cyst was by Zuckerkandl in 1882 ⁽²⁾.

This reported case of relatively rare unilateral cyst is the second case reported in Saudi Arabia up to the best knowledge; the first case was excised surgically by sublabial approach.

CASE REPORT

A 36 -years - old women presented with left Nasolabial fullness and nasal obstruction for one year, the patient noticed a painless nasal mass for a duration of six months. Examination revealed left Nasolabial swelling located

inferior to the inferior turbinate extending laterally into the cheeks (Figs. 1,2).

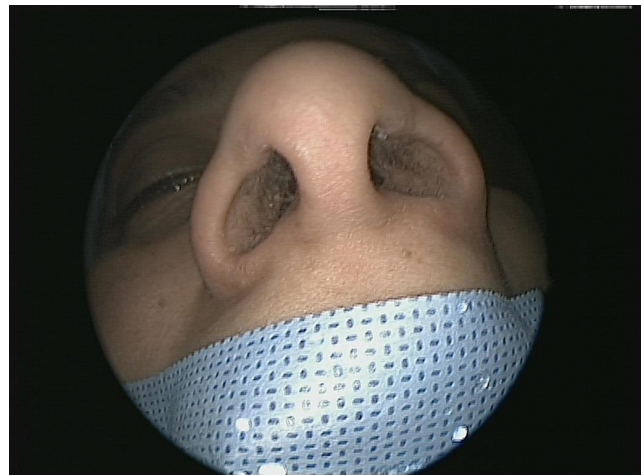

Fig 1

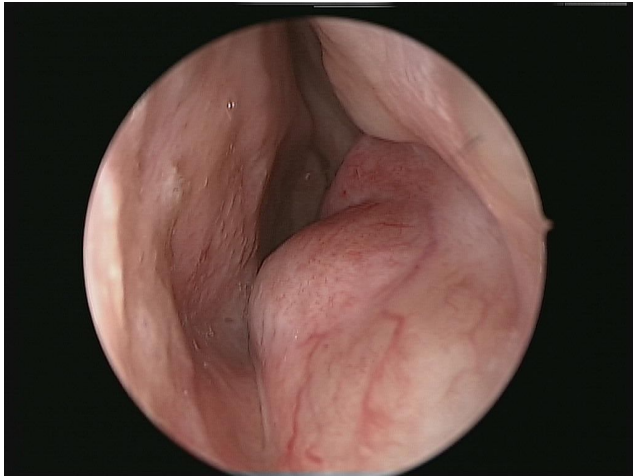


Fig 2

Computed tomography (CT) scan showed ovoid well-circumscribed extraosseous soft tissue lesion at the alar base lateral to the piriform aperture with bony involvement (Fig. 3). Magnetic resonance imaging (MRI) report showed hyperintense cyst content relative to cerebrospinal fluid in T1- weighted and isointense in T2-weighted images suggesting Nasolabial cyst (Fig. 4).

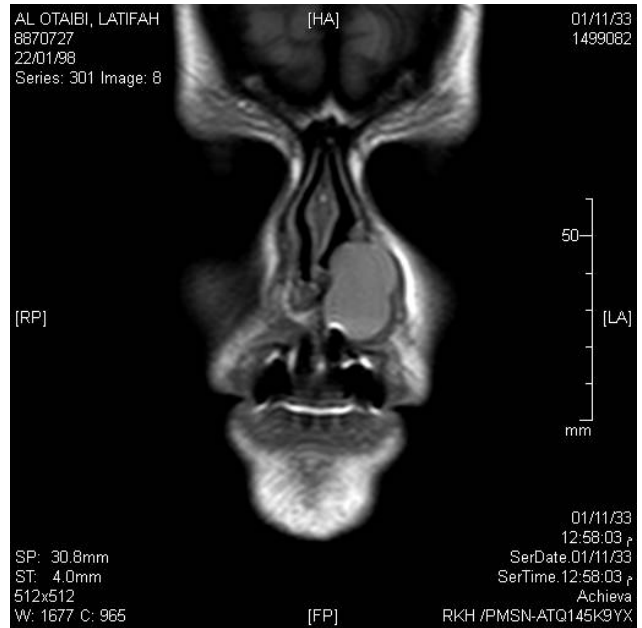


Fig 4

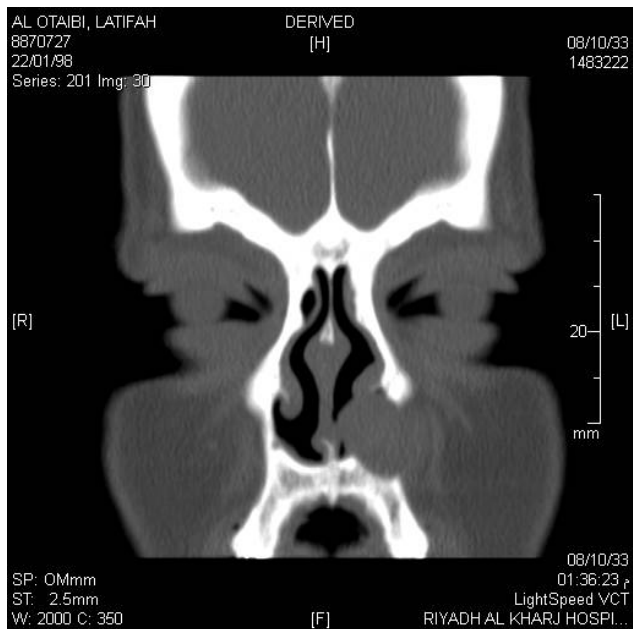


Fig 3

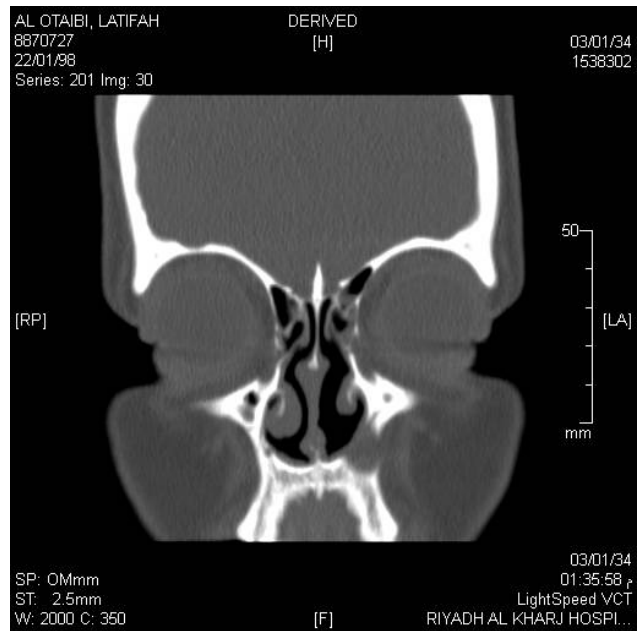


Fig 5

Nasolabial cyst: Case Report

Endoscopic transnasal excision of the cyst was carried out with the use of the debridor.

During the procedure the nasal cavity was shrunk with nasal gauzes for 5 minutes. Under endoscopic guidance, an incision was made along the anterior border of the protruding cyst. The roof of the cyst wall and the nasal mucosa above it were excised. The opening of the cyst was widely widened and the cyst mucosal lining was dissected and excised to minimize recurrence. Meanwhile, the edges of the nasal mucosa and the cyst lining were trimmed smooth with the debridor. Loose nasal packing was then applied. The patient was discharged with no complications after 16 hours.

Histopathology showed respiratory epithelium with ciliated pseudostratified columnar cells.

Patient follow up showed complete healing by endoscopic examination and by CT scan (Fig. 5) and no recurrence for more than a year.

DISCUSSION

Nasolabial cysts account for only 0.7% of all maxillary and mandibular cysts. (4,5)

Two theories have been suggested to explain the origin of Nasolabial cyst. (2)

The first theory as Klestadt in 1913 suggested it arises from trapped epithelium at the point where the maxillary, medial nasal, and lateral nasal processes fuse which become inclusion cyst. This hypothesis has been discarded due to lack of evidence.

Bruggeman in 1920 had suggested that Nasolabial cysts are the nasolacrimal ducts remnants and this is supported by the fact that both share the same lining pseudostratified columnar epithelium.

In spite of its developmental in origin, our patient is 36 years old, Chao et al (3) in his series of 23 patients reported that all patients are in the fourth and fifth decades of life, Zahirrudin et al (6) reported in his series mean age of 43.2 years, Yuen et al (7) in a series of 18 patients the mean age was 41 years, and Abou-Elhamd (8) reported a case from Saudi Arabia of 38 years old.

Nasolabial cysts predominantly occur in females with male to female incidence ratios ranging from 2.7:1 to 3.7:1. (9-11)

Most commonly the Nasolabial cyst present as unilateral lesion without side preference as in the reported case, but bilateral lesion have been reported. (11,12)

The lead clinical symptom is usually painless swelling as the reported case, but pain if present could be a symptom when secondary infection of the cyst content occurs. There is a reported case of malignant degeneration of the cyst in the literature. (13)

The differential diagnosis for a painless vestibular soft tissue swelling within the antero-maxillary-alar region include odontogenic, developmental and neoplastic lesions. (14)

Nasolabial cyst appears as homogenous non-enhancing cystic mass anterior to the piriform apparatus showing no erosion of the underlying maxilla on CT scan.

It can differentiate from other cyst; therefore CT scan is a useful tool for diagnosis and determination of the surgical approach. (15)

Nasolabial cyst histo-pathological diagnosis by routine microscopic examination and clinical correlation.

The most commonly used surgical approach is sublabial approach which carries low recurrence rate but often caused defect in the nasal floor, Su et al (16) the first to report the transnasal endoscopic marsupialization for Nasolabial cysts 1999 and compared the two approaches describing the endoscopic approach as simple, take short duration and less blood loss.

Transnasal marsupialization of Nasolabial cyst is cost effective compared to sublabial approach because in transnasal approach as reported by Chao et al (3) hospitalization is short, shorter duration of surgery and significantly lower incidence of postoperative complications such as facial swelling, numbness, and toothache. In the present case endoscopic approach was used to completely excise the cyst with widened cyst incision to prevent recurrence, patient experienced no complications postoperatively, and no recurrence for a year.

CONCLUSION

Although Nasolabial cysts are rarely presented to the otolaryngologist but should be considered in the differential diagnosis of Nasolabial masses.

Endoscopic approach with the use of debridor is a simple, cost effective, with almost no postoperative complications. With the use of angled telescopes complete excision is possible.

REFERENCES

1. Toribio Y, Roehrl M. The Nasolabial Cyst A non-odontogenic oral cyst related to nasolacrimal duct epithelium. Arch Pathol Lab Med. 2011;135:1499-503.
2. Patil K, Mahima VG, Divya A. Kelstadt's cyst: A rarity. Indian journal dental research. 2007;18:23-6.
3. Chao W, Huang C, Chang P, et al. Management of Nasolabial cysts by transnasal endoscopic marsupialization. 2009;135:932-5.
4. Allard RH. Nasolabial cyst: review of the literature and report of 7 cases. Int. J oral surg. 1982;11:351-9.
5. Chol JH, Cho JH, Kang HJ, et al. Nasolabial cyst: a retrospective analysis of 18 cases. Ear Nose Throat J. 2002;81:94-6.
6. Zahirrudin Z, Gendeh B, Tan G, et al. Nasolabial cyst: Presentation and management. The Internet journal of otorhinolaryngology. 2009;9. DOI: 10.5580/11a3.
7. Yuen HW, Julian LCW, Samuel CLY. Nasolabial cysts: clinical features, diagnosis, and treatment. British Journal of Oral and Maxillofacial Surgery. 2007;45:293-7.
8. Abou-Elhamd KA. A case of Nasolabial cyst with CT and MRI features. The Internet Journal of Otorhinolaryngology. 2009;9. DOI: 10.5580/243e.
9. CHinellato LE, Damante JH. Contribution of radiographs to the diagnosis of naso-alveolar cyst. Oral Surg Oral Med Oral Pathol. 1984;58:729-35.
10. Kuriloff DB. The Nasolabial cyst-nasal hamartoma. Otolaryngol Head Neck Surg. 1987;96:268-72.
11. Van Bruggen AP, Shear M, Du preez IJ, Van wyk DP, et al. Nasolabial cysts: a report of 10 cases and a review of the literature. J Dent Assoc S Afr. 1985;40:15-19.
12. Marcoviceanu MP, Metzger MC, Deppe H, et al. Report of rare bilateral Nasolabial cysts. J Craniomaxillofac Surg. 2009;37:83-86.
13. Lopez-Rios F, Lassaletta- Atienza L, Domingo-Carrasco C, et al. "Nsolabial cyst: report of a case with extensive apocrine change". Oral Surgery, Oral Medicine, Oral Pathology, Oral Radiology, and Endodontics. 1997;84:404-6.
14. Kuriloff DB. The Nasolabial cyst-nasal hamartoma. Otolaryngol Head Neck Surg. 1987;96:268-72.
15. Kato H, Kanematsu M, Kusunoki Y, et al. Nasoalveolar cyst: imaging finding in three cases. Clin Imaging. 2007;31:206-9.
16. Su CY, Chien CY, Hwang CF. Anew transnasal approach to endoscopic marsupialization of the Nasolabial cyst. Laryngoscope. 1999;109:1116-8.