



## How I Do It?

# Microdebrider Assisted Inferior Turbinoplasty (MAST)

**Mohannad Al-Qudah, Diala Al-Mardeeni**

Department of Otolaryngology HNS Surgery, Jordan University of Science & Technology, Irbid, Jordan

Correspondence to: Mohannad Al-Qudah, Email: malqudah@gmail.com

***Persistent medically resistant inferior turbinate hypertrophy is a common cause of chronic nasal obstruction. This condition is usually treated surgically. Different surgical techniques have been described, some intended to provide temporary relief and others advocated to have good long outcome. Herein we describe our surgical method in treating this condition using power instrumentation.***

## INTRODUCTION

Nasal obstruction is a common symptom of nasal pathology. Advancement in endoscopic and radiology visualization allowed better evaluation of the underlying etiology. Turbinate enlargement is not any more shadowed by nasal septal deviation as the main cause of nasal obstruction.<sup>(1)</sup> Because of awareness of its important role in nasal obstruction, different surgical techniques have been described to address this condition.<sup>(2-4)</sup> In this report, we describe how surgically we treated inferior turbinate hypertrophy using microdebrider.

**Indication:** Inferior turbinate hypertrophy secondary to soft tissue inflammation that failed to respond to medical treatment.

### **Contraindications:**

1. Inferior turbinate hypertrophy due to an enlarged turbinate bone.
2. Bleeding tendency.
3. Acute rhinitis.

**Especial Surgical Instrumentations:** 4-mm diameter, 0° nasal endoscope (Hopkins II, Karl Storz, Germany) and straight microdebrider (XOMED, Medtronic, USA) (3.5-mm tip with a serrated blade).

### **Technique:**

- A. Setting: Ambulatory day case.
- B. Position: Reverse Trendlberg with 30° head up.
- C. Anesthesia: General anesthesia.
- D. Procedure:
  1. The head of inferior turbinate is injected with 2-3 ml of local anesthesia containing 1% lidocaine in 1:70,000 adrenalin. The body and tail of inferior turbinate are infiltrated with normal saline to facilitate flap elevation.
  2. The inferior turbinate fractured medially. We found visualization and instruments handling are easier in this plane.
  3. Using number 15 blade, a vertical incision at the most anterior end of the inferior turbinate performed and this taken down to the bone.

4. A non-sharp elevator utilized to create a flap tunnel along the medial and inferior surface of the turbinate till its posterior end. A great attention of care should be applied at the level of inferior turbinate neck where the turbinate directed more inferiorly; this is the most common site to tear mucosa.
5. The microdebrider blade facing the bony wall passed through the created plane with off suction mode until the posterior end of the inferior turbinate reached, now the suction turned on and the blade rotate at a speed of 2300 to 3000 rpm to remove redundant erectile tissue. After this any redundant mucosa from the inferior and lateral wall of the inferior turbinate removed.
6. The inferior turbinate replaced back to its lateral position. Proper sized nasal pack inserted to prevent postoperative bleeding and stent mucosal flap.

**Postoperative Instructions:** Patients are usually discharged home when recover. Nasal pack removed on the next day and nasal irrigation started. We usually describe a short course of oral Antibiotic.

### DISCUSSION

Our modern understanding of the role of inferior turbinate in air way physiology and the concept of mucosal preservation in sinus surgery made old procedures for turbinate hypertrophy, such as turbinectomy, as obsolete and thus create a wide area for development of different techniques to approach turbinate hypertrophy.<sup>(2-4)</sup>

Today, the presence of many surgical options for treating inferior turbinate hypertrophy indicates how much common is the condition, the absence of concise agreement between rhinologists in regards of the best modality to approach these patients and the implication of modern technology in this field.

Each technique has its advantages and limitations. We have been using MAST for more than 7 years and considered it as the surgical treatment of choice for medically resistant inferior turbinate hypertrophy. Procedure disadvantages are obvious: the need of general anesthesia and the relative cost of equipments, in the other hand the surgery is safe with low morbidity rate, well tolerated, mucosal preservative and easily can combine with other sino-nasal procedures.

Microdebrider design, a suction-based powered instrument with a blunt end and guarded inner 90 oscillating or rotating blade, affords excellent control and precision for cutting of soft tissue, resection and removing

only tissue suctioned into the rotating hole, while preserving surrounding mucosa.<sup>(5)</sup>

In our practice, we usually schedule these patients to be seen at day 7 postoperative where we noticed that small crust formation is common and can be easily cleaned under local anesthesia, any adhesion especially if the procedure combined with other nasal surgeries can also be addressed. We arrange the 2nd visit at 3rd week, at this time the mucosa healed completely and the patients achieved the maximum surgical benefit. After that we followed patients as a case by case need. Many of our patients are happy with the outcome and had satisfactory results upon long follow up period (Figs. 1,2).

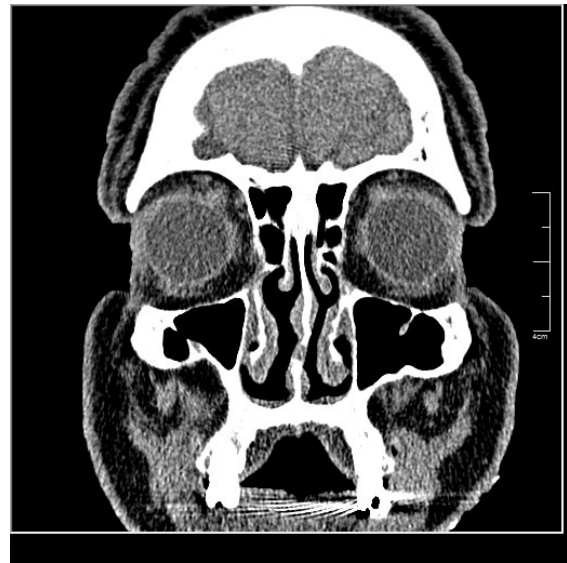


Fig 1. CT scan of sinonasal region, Soft tissue window, showed bilateral patent nasal cavity 4 year after MAST.

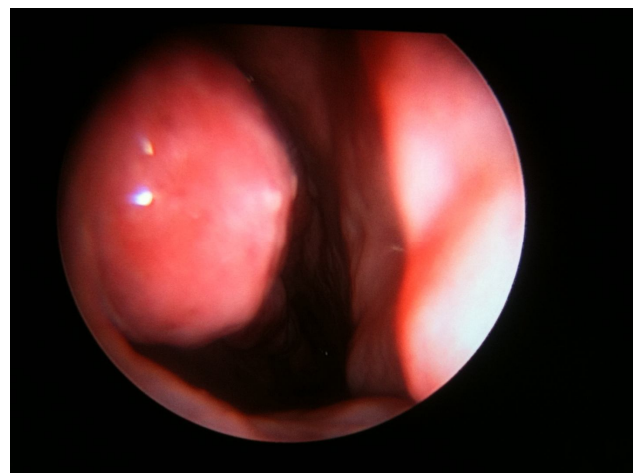


Fig 2. 0 endoscopic view of the right nasal cavity for a patient 5 years post MAST.

## Microdebrider Assisted Inferior Turbinoplasty (MAST)

It should be understood that nasal obstruction may be caused by more than one predisposing factor. Nasal septal deviation, turbinate hypertrophy and even adenoid hypertrophy can be seen together especially in allergic and environmental exposed patients. In such cases a thorough clinical assessment is needed to detect the primary cause of nasal obstruction that should be first addressed.<sup>(1)</sup>

The term Turbinoplasty covers various methods of intratubinal surgical reduction of the inferior turbinate volume with preservation of the mucosa.<sup>(4)</sup> Five years after successful use of power instruments in endoscopic sinus surgery, turbinate surgery took advantage of this technology and MAST had been introduced providing less tissue trauma, clearer operative field and long term patent nasal cavity.<sup>(5)</sup> Since then many modifications in the techniques have been released, each probably fit certain group of patients and certain geographical region.<sup>(6,7)</sup> Because of the high rate of allergy and irritation as well as the presence of four season weather in our area, we adapted this modification of being a bit more aggressive in removing hypertrophied mucosa from the inferior and lateral wall of the inferior turbinate.

## REFERENCES

1. Jessen M, Malm L. Definition, prevalence and development of nasal obstruction. *Allergy*. 1997;52(40 Suppl).
2. Lee k, Hwang p, Kingdom T. Operative techniques in otolaryngology--head and neck surgery. 2001;12:107-11.
3. Atef A, Mosleh M, El Bosraty H, Abd El Fatah G, Fathi A. Bipolar radiofrequency volumetric tissue reduction of inferior turbinate: does the number of treatment sessions influence the final outcome?. *Am J Rhinol*. 2006;20:25-31.
4. Hol MK, HuizingEH. Treatment of inferior turbinate pathology: a review and critical evaluation of the different techniques. *Rhinology*. 2000; 38:157-66.
5. Hackman TG, Ferguson BJ. Powered instrumentation and tissue effects in the nose and paranasal sinuses *Curr Opin Otolaryngol Head Neck Surg*. 2005;13:22-6.
6. Chen YL, Tan CT, Huang HM. Long-term efficacy of microdebrider-assisted inferior turbinoplasty with lateralization for hypertrophic inferior turbinates in patients with perennial allergic rhinitis. *Laryngoscope*. 2008;118:1270-4.
7. Wu CC, Lee SY, Hsu CJ, Yeh TH. Patients with positive allergen test have less favorable outcome after endoscopic microdebrider-assisted inferior turbinoplasty. *Am J Rhinol*. 2008;22:20-3.