



A long term follows up after resection of an intraosseous haemangioma of the anterior end of the inferior turbinate

Omar A. El-Banhawy, Ali Al Amri, Ibrahiem El-Desoky

Department of Otorhinolaryngology, Faculty of Medicine, El Menoufyia University, Egypt, Department of ENT Surgery, Prince Salman Hospital, Kingdom of Saudi Arabia, Pathology Department, Faculty of Medicine, Mansoura University, Egypt.

Correspondence to: Omar A. El-Banhawy, Email: oelbanhawy@ hotmail.com

Intraosseous haemangiomas are uncommon, constituting less than 1% of all osseous tumors. Involvements of the facial bones are rare, and most commonly affects the maxilla, mandible and nasal bones. We report a case of an intraosseous hemangioma of the anterior end of the inferior turbinate associated with soft tissue extension. The management and pathogenesis of this case is discussed. The case is followed up for 9 years without recurrence or other related complication. To the best of our knowledge, this is the first reported case in the English literatures of this pathological entity in this location with this long term follow up.

Keywords: Haemangioma; nasal turbinate; facial bones.

INTRODUCTION

Haemangioma is a benign vascular lesion. It is now thought to be a hamartoma with anomalous proliferation of endothelial lining the vascular channels.⁽¹⁾ Over half of all haemangiomas are located in the head and neck regions.⁽²⁾ Intraosseous haemangioma of the facial bones are rare and most commonly arise in the maxilla, mandible, and nasal bones and show different behavior.⁽²⁾

We present a case of an intraosseous haemangioma at the anterior end of the inferior turbinate associated with facial soft tissue extension and its 9 years long term follow up. To the best of our knowledge, this is the first reported case in the English literatures of this pathological entity in this location.

CASE REPORT

A 36 -year-old man was presented with 6 years history of painless slowly growing swelling of the left cheek. Three

years before seeing, he was admitted once to a hospital to control a severe left sided epistaxis with anterior nasal pack. Preoperative examination revealed ill defined, immobile non-expansile soft tissue swelling 2.5 x 2 cm at the left nasolabial junction with no change of the color of the overlying intact skin.

Nasal endoscopy revealed obliteration of the anterior part of the left inferior meatus with intact overlying mucosa. Sub-labial examination showed two bluish cystic 2 mm x 3mm swellings (Fig. 1).

Pre and post contrast axial and coronal computed tomography (CT) scan showed localized non-enhanced mildly expansile osteolytic bony lesion with honeycomb appearance involving the left anterior end of the inferior nasal turbinate and nasal process of the left maxilla associated with non-enhanced soft tissue extension (Fig. 2). As the lesion did not show any enhancement a decision was taken not to perform angiography or embolization.

A long term follow up after resection of an intraosseous haemangioma of the anterior end of the inferior turbinate

Intraoperative assessments of the cystic swellings showed bloody aspirate with severe bleeding from puncture site. Measurements to minimize intraoperative bleeding were done including elevation of the patient head, applying hypotensive anesthesia, approaching the lesion from the periphery with early control of bleeding using monopolar and bipolar diathermy.

Endoscopic assisted sublabial facial degloving approach was performed and lower half medial maxillectomy was done. The affected bone was spongy friable and removed in piece meal. The bleeding was ceased when the entire lesion (bony and the associated soft tissue) was excised. The intraoperative blood loss was 1.2 liter and 1.5 units of blood were transfused.

Macroscopically, the affected nasal turbinate bone was very vascular with spongy appearance (Fig. 3). The microscopic appearance of the tumor showed the characteristic histological picture of cavernous haemangioma with thin walled blood vessels of several sizes lined by endothelium that infiltrate between the bone trabeculae that were filled by haemolyzed blood.

Long term 9 years postoperative course of the patient was uneventful without recurrence or other related complication (Fig. 4).

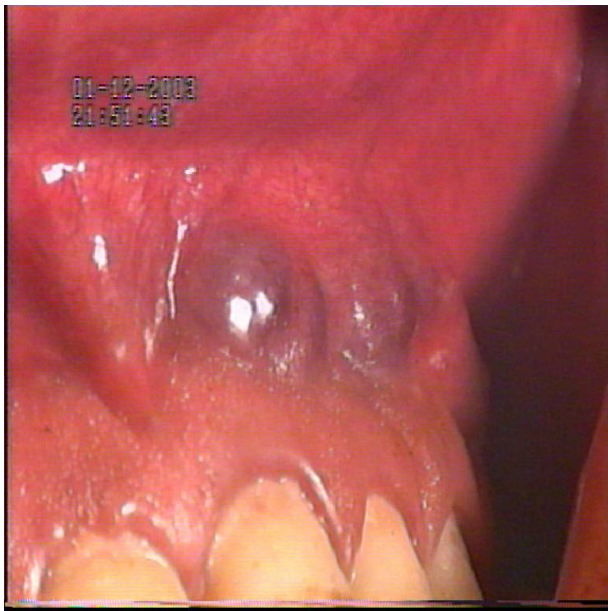
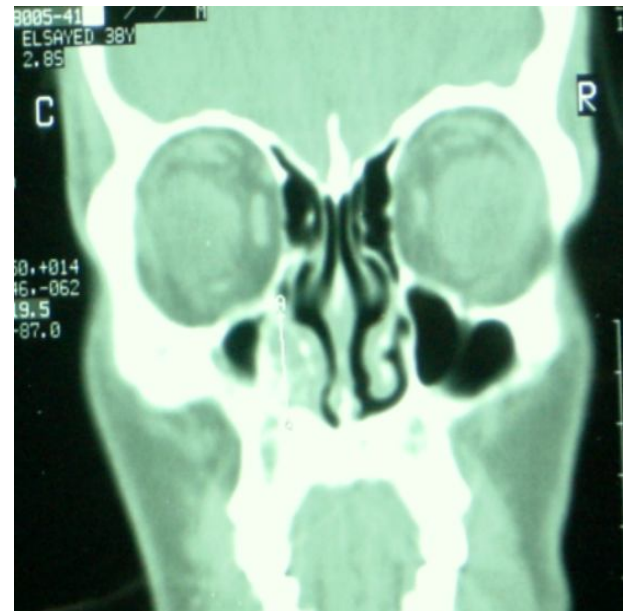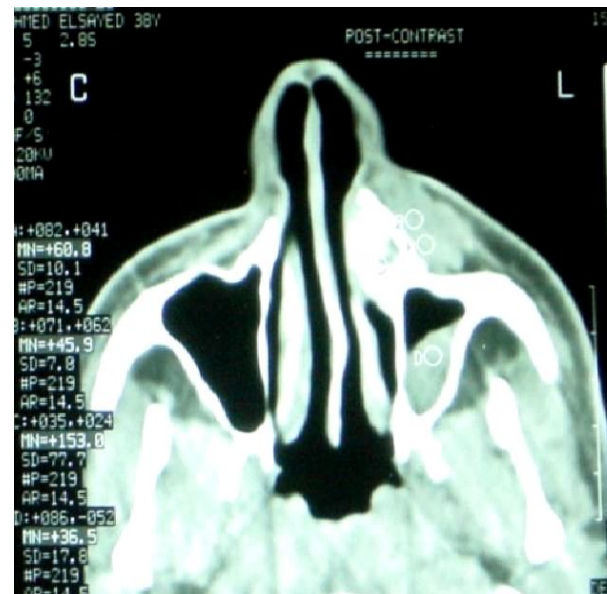


Fig 1. Preoperative sub-labial view of the two bluish cystic swellings associated with the intraosseous hemangioma of anterior end of the inferior nasal turbinate.



A



B

Fig 2. Preoperative post-contrast coronal (A) and axial (B) CT scan of paranasal sinuses showing an expansile bony mass of "honeycomb" appearance involving the left anterior end of the inferior turbinate and nasal process of the left maxilla associated with non-enhanced subcutaneous soft tissue extension.

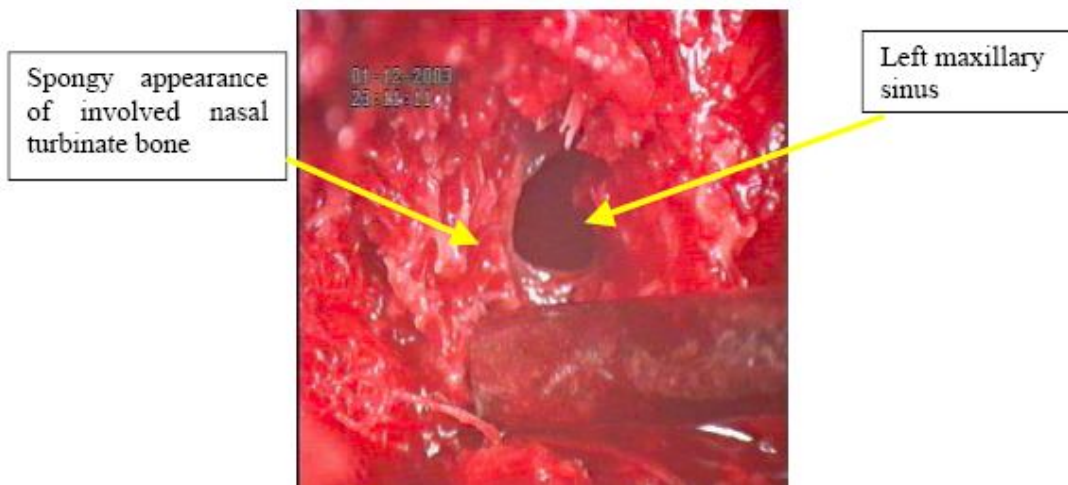


Fig 3. Intraoperative view of the intraosseous hemangioma of the left anterior end of the inferior nasal turbinate is showing the coarse spongy character of the turbinate bone.

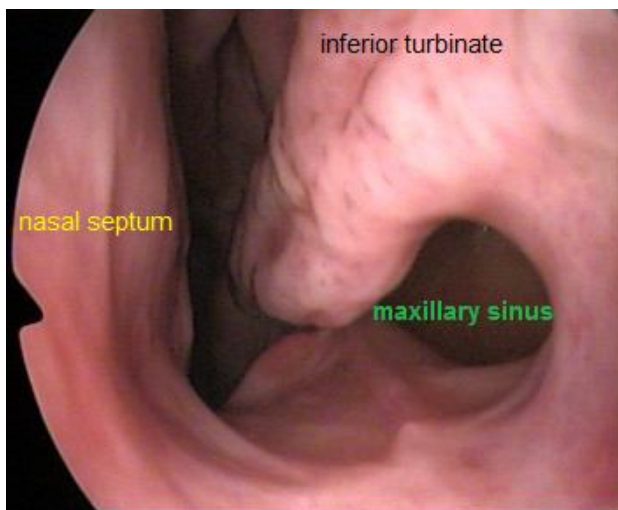


Fig 4. Postoperative endoscopic view (9 years after surgery) of left nasal cavity of the studied case. It showed the site of the harvested part of the inferior turbinate through which the left maxillary sinus appears healthy.

DISCUSSION

Hemangiomas, which were originally classified as vascular neoplasms, are now thought to be hamartomas with an anomalous proliferation of endothelial-lined vascular channels.⁽¹⁾ Osseous hemangiomas are slow in growing, and treatment is not always necessary.

Indications for surgery include correction of a mass effect, control of hemorrhage, and cosmesis.⁽³⁾

Patients with intraosseous hemangiomas of the facial bones usually present in the fourth decade of life with a tender or a painless slowly growing swellings with female predominance (3:1). The lesion is more common on the left side, and there may be associated prior trauma.⁽²⁻⁴⁾ Apart from its site the current case showed the same clinical presentation as reported in the literature as it occurred in the 4th decade, left sided with slowly growing painless cheek swelling.

In the current case the clinical diagnosis was difficult and the initial clinical impression favored fibrous dysplasia. Preoperative biopsy was not planned because of the vascular nature of the sublabial part of the lesion that might result in severe hemorrhage.

CT scan is considered the most useful imaging techniques for facial bones and paranasal sinuses because of its excellent characterization of bone trabecular and cortical detail.⁽²⁻⁴⁾ The CT appearances of intraosseous hemangiomas of the facial bones are variable with a characteristic sunburst pattern of radiating trabeculae. "Soap bubble" and "honeycomb" configurations may also occur.⁽²⁻⁴⁻⁵⁾

In the current case the non-enhancement pattern with "honeycomb" configurations of the left anterior end of the inferior turbinate and the soft tissue extension made the CT diagnosis quite difficult. The non-enhancement pattern of the lesion could be due to hemorrhage within the

A long term follow up after resection of an intraosseous haemangioma of the anterior end of the inferior turbinate

tumor. Furthermore, phleboliths, which are characteristic of cavernous hemangioma, could occur with obliteration of the feeding blood vessels.

Angiography and transarterial embolization for the management of intraosseous hemangiomas were recommended but we did not do it as the lesion did not show any enhancement on CT.

Intraosseous hemangiomas were reported to bleed profusely intraoperative and the surgical approach should be chosen to obtain an unrestricted field of view to control the hemorrhage.⁽³⁾ In the current case the endoscopic assisted sublabial facial degloving approach was employed due to its minimal invasiveness and to ensure better control of bleeding with complete resection of the bony and soft tissue lesion. Keeping in mind the vascular nature of the lesion and profuse bleeding might occur so blood transfusion was planned.

CONCLUSION

Preoperative diagnosis of intraosseous hemangioma of the anterior end of the inferior turbinate should be considered in any osteolytic lesion. Endoscopic assisted sublabial facial degloving is a useful approach for complete lesion resection and to control intraoperative bleeding. Surgeons must be aware that this lesion is highly vascular and they should to take the necessary precautions before surgery. The long term follow- up (9 years) without recurrence or any other related complication demonstrates the validity of our approach.

REFERENCES

1. Iwata N, Hattori K, Nakagawa T, Tsujimura T. Hemangioma of the nasal cavity: a clinicopathologic study. *Auris Nasus Larynx*. 2002;29:335-9.
2. Clauser L, Meneghini A, Riga M, et al. Haemangioma of the zygoma: report of two cases with a review of the literature. *J Craniomaxillofac Surg*. 1991;19:353-8.
3. Firooznia H, Golimbu C, Rafii M, Rauchning W, Weinreb J. *MRI and CT of the Musculoskeletal System*. St Louis: Mosby. 1992:630.
4. Konior R, Kelly T, Hemmer D. Intraosseous zygomatic hemangioma. *Otolaryngol Head Neck Surg*. 1999;121:122-5.
5. Akiyama K, Karaki M, Osaki Y, Takeda J, Mori N. Intraosseous cavernous hemangioma of the middle turbinate. *Auris Nasus Larynx*. 2011;38:516-8.