

# Endoscopic-assisted rigid internal fixation of anterior wall frontal sinus fractures

Tarek A. Emara<sup>a</sup>, Ashraf E. OdaBasha<sup>a</sup>, Tharwat A. Omara<sup>b</sup>,  
Mohamad S. Abdelazem<sup>a</sup>, Ahmed M. Anany<sup>a</sup>

<sup>a</sup>Department of Otolaryngology Head and Neck Surgery, Faculty of Medicine, Zagazig University, <sup>b</sup>Department of Oral and Maxillofacial Surgery, Al-Ahrar General Hospital, Zagazig, Egypt

Correspondence to Tarek A. Emara, MD, 35 Albahr Street, Zagazig, Egypt Postal cod 1115, Department of Otolaryngology Head and Neck Surgery, Faculty of Medicine, Zagazig University, Zagazig, Egypt  
e-mail: tarek.emara@yahoo.com

**Received** 24 February 2020

**Accepted** 09 April 2020

**Published** 21 January 2021

**Pan Arab Journal of Rhinology**  
2020, 10:45–49

## Objectives

Isolated anterior wall frontal sinus fractures are usually managed through a coronal approach, with its potential complications such as big scar, alopecia, and paresthesia. This study evaluates the endoscopic repair of isolated anterior wall frontal sinus fractures with rigid internal fixation.

## Study design

This was a prospective clinical trial.

## Setting

This study was conducted at a tertiary care academic medical center.

## Patients and methods

A total of 24 patients with isolated anterior wall frontal sinus fractures, documented with computed tomographic (CT) scans, were treated from 2010 to 2013. All were men with a mean age of 31 years (range, 21–43 years). Via a 10-mm skin incision placed in a skin crease, an endoscopic reduction by microplate fixation of the displaced bony segments was achieved.

## Results

Three patients were excluded from the study owing to incomplete follow-up. Follow-up ranged from 13 to 29 months, with an average of 17 months. Contour deformities were perfectly restored, and cosmetic results were acceptable in all patients. Postoperative CT scans showed an excellent anatomic restoration of the frontal sinus contour in 17 patients. In four patients who had the anterior frontal sinus fractures affecting the superior orbital rime, the postoperative CT scans showed a suboptimal reduction of the bony fragments; however, they were satisfying with the forehead aesthetic contour. None of the patients complained of sinusitis or other related complications.

## Conclusion

Isolated anterior wall frontal sinus fractures can be successfully treated endoscopically by microplate fixation. This method is a safe procedure that can be done with ease and minimal morbidity to avoid the comorbidities associated with the coronal approach.

Level of evidence: The level of evidence is IIb.

## Keywords:

anterior wall frontal sinus fractures, endoscopic repair, frontal sinus outflow tract, rigid internal fixation

Pan Arab J Rhinol 10:45–49  
© 2021 2090-7640

## Introduction

Frontal sinus fractures constitute 5–15% of all facial injuries [1,2]. Surgical intervention aims to isolate and protect the vital intracranial structures to avoid possible serious complications (meningitis, brain injuries, mucoceles, etc.) and restore the normal forehead aesthetics. Management of fractures affecting the posterior table or the frontal sinus outflow tract is difficult owing to associated possibility of meningitis, brain injury, mucoceles, and impairment of the frontal sinus drainage and ventilation. At the same time, isolated anterior table frontal sinus fractures carry a minor risk of long-term morbidity and are consensually managed for aesthetic purposes [3,4].

Traditionally, repair of the anterior wall frontal sinus fractures is accomplished via a coronal incision. This approach has a high success rate of fracture repair, but

at the same time, it has a relatively high morbidity like long scar, numbness of the forehead, alopecia, and possible facial nerve injury [5–7].

Throughout the literature studies, many authors have described endoscopic-assisted approach for dealing with these fractures to replace the need for coronal incision with its surgical complications. Kim *et al.* [8] described an endoscopic onlay fracture camouflage by Medpore without fracture reduction or fixation. Endoscopic-assisted closed reduction of the frontal sinus anterior wall fractures involving a small incision at the forehead, around eyebrow, and at hairline has

This is an open access journal, and articles are distributed under the terms of the Creative Commons Attribution-NonCommercial-ShareAlike 4.0 License, which allows others to remix, tweak, and build upon the work non-commercially, as long as appropriate credit is given and the new creations are licensed under the identical terms.

been described [9,10]. Yoo *et al.* [11] described a case report of a 14-year-old boy with frontal sinus anterior wall fractures who was treated by endoscopic transnasal approach with no external incision or fixation. In this study, we described an endoscopic repair of anterior frontal sinus fractures with rigid internal fixation by titanium microplate system.

## Patients and methods

### Study design

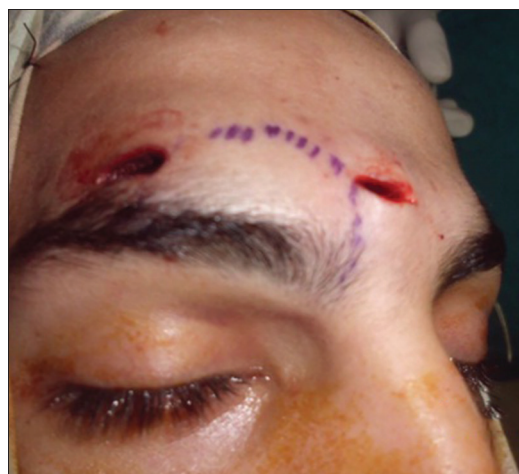From January 2010 to December 2013, 24 patients with frontal sinus anterior wall fractures (all were men with a mean age of 31 years; range, 21–43 years) from the Department of Otolaryngology – Head and Neck Surgery, Zagazig University Hospitals, Zagazig, Egypt, were included in this study. Patients with posterior wall fractures, cerebrospinal fluid rhinorrhea, and frontal sinus outflow tract injuries were excluded from the study.

Clinical evaluation included complete history to explain mechanism of injury and any previous nasal or paranasal sinus surgery, clinical examination, and high-resolution axial CT scan with reconstructed coronal and sagittal cuts to outline fracture type, status of the frontal sinus outflow tract, and accompanying other craniofacial fractures. The nature of the fractures and protocol of surgical procedure with its possible complications with possibility to shift to external approach were discussed with the patients and their family members. This protocol involves endoscopic reconstruction of the frontal sinus anterior wall fractures with rigid internal fixation by Titanium Microsystems via a 1-cm skin incision located on both sides of the fractures. Informed written consent was obtained from the patients, and Zagazig University Institutional Review Board (IRB) approved the research plan.

### Surgical procedure

Local preparation and routine dressing was done, and the limits of the depressed fractures of the anterior wall of frontal sinus were delineated by a marker pen (Fig. 1). Two incision lines were marked on both sides of depressed bone segments. A local infiltration of 5 ml of 1: 200 000 epinephrine and 2% lidocaine was achieved. The sites and courses of supratrochlear and supraorbital neurovascular bundles were demarcated, so as not to be damaged during skin incision. Then, a 10-mm incision was located within a skin crease at the two marked sites and deepened to the fracture. A subperiosteal 0° endoscopic-guided dissection of soft tissue over and 1 cm around the depressed bone segments was done with preservation of supratrochlear

Figure 1



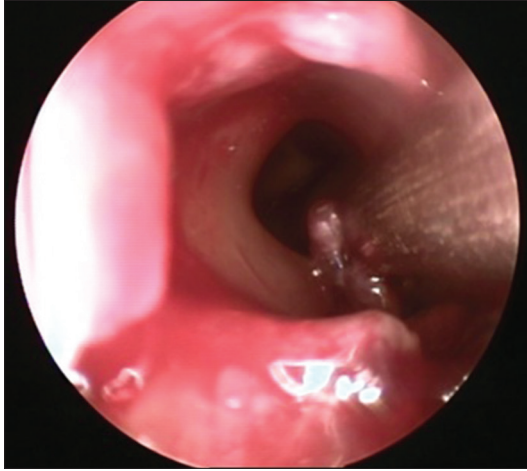
Depressed fractures of the anterior wall of frontal sinus outlined by a marker pen.

and supraorbital nerves. A 5-mm drill hole opening was made in the depressed bony fragment to assist in the introduction of the 30° telescope into frontal sinus cavity. Once inside the sinus cavity, with the help of 30° endoscope, a periosteal elevator was located under the depressed bony fragments of the frontal sinus anterior wall with gentle pressure, and reduction of the displaced bones to its normal anatomical position was done to restore the normal depth of the frontal sinus anteroposterior diameter. Assessment of the frontal sinus outflow tract patency was done. Retained secretions and blood clots were removed by continuing suction and irrigation. Occasionally, separated bony spicules were seen obstructing the infundibulum and/or the ostium of the frontal outflow tract. Removal of these bony spicules by repeated suction and small forceps was achieved to maintain a normal frontal sinus drainage and ventilation (Fig. 2).

Titanium microplates were prepared and adjusted to cross the fracture lines over the reduced fractured anterior wall of frontal sinus. Then, two microscrews were used to fix the microplates to the adjacent nonfractured frontal bone. Through a percutaneous route the fractured anterior frontal sinus wall were fixated with microscrews helped with Intrasinus support of the reduced fracture segments with periosteal elevator (Fig. 3).

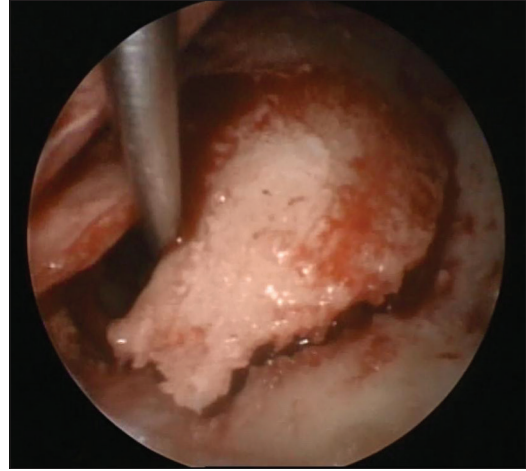After being satisfying with bone reduction and fixation (Fig. 4), endoscopic assessment of the patency of the nasofrontal outflow tract and the sites of screws was achieved (Fig. 5). In most patients, one titanium microplate was adequate to restore normal contour of the frontal sinus, and in two patients, two microplates were placed. The 10-mm incisions were closed. Postoperative evaluation was done by clinical

Figure 2



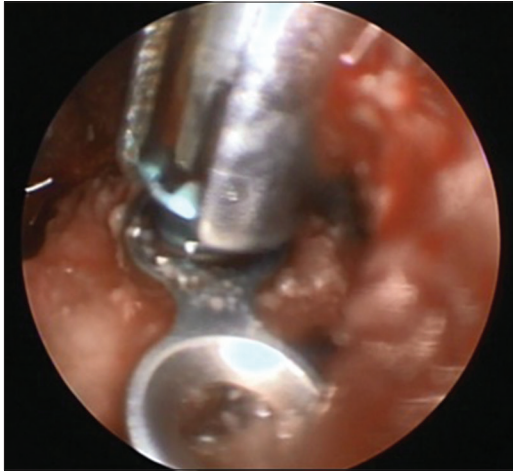
Endoscopic view from within the frontal sinus cavity showing removal of bony spicules by suction, out of the frontal ostium to maintain a normal frontal sinus drainage and ventilation.

Figure 3



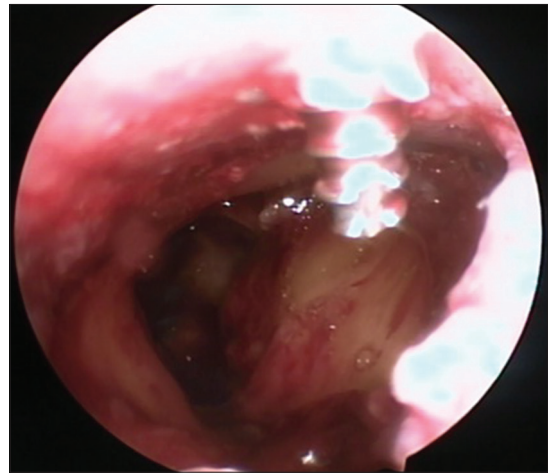
Intranasal support of the reduced fracture segment during microscrews fixation with periosteal elevator.

Figure 4



Endoscopic view showing a good alignment of the fracture anterior frontal sinus with microplate and screw fixation.

Figure 5



Endoscopic view within the cavity of the frontal sinus, showing a patent frontal sinus outflow tract and the tips of the microscrew fixing the anterior wall.

examination 1 week, 1 month, 6 months, and a year after surgery. Computed tomographic (CT) scans were done 3 months after the surgery to evaluate the status of the forehead frontal sinus in terms of ventilation, drainage, and esthetic contour.

## Results

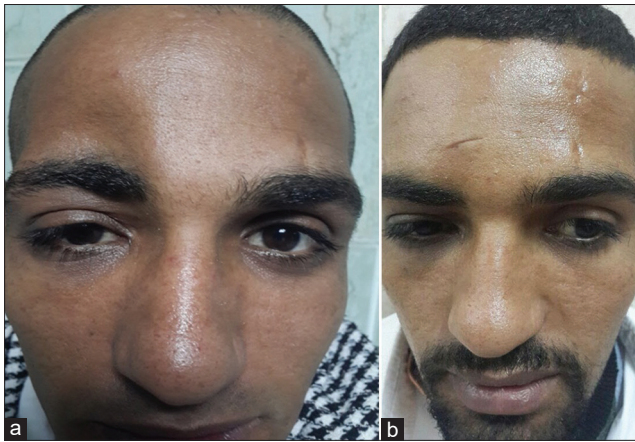Overall, three patients were removed from the study owing to incomplete follow-up, whereas 21 patients completed the postoperative follow-up. All were men with a mean age of 31 years, range 21–43 years. Postoperative follow-up ranged from 13 to 29 months, with a mean of 21 months. Forehead contour deformities were successfully restored, and aesthetic results at the incision lines were acceptable in all patients (Fig. 6). A total of three patients complained of slight

hypoesthesia in the forehead, which was improved at 15–24 months after the operation. Postoperative CT scans revealed an excellent restoration of the frontal sinus contour in 17 patients (Fig. 7). In four patients, who had the anterior frontal sinus fractures affecting the superior orbital rime, the postoperative CT scans revealed a suboptimal reduction of the bony fragments; however, all these four patients were satisfied with forehead aesthetic contour. None of the patients experienced sinusitis or other related complications.

## Discussion

The aims of the surgical management of frontal sinus fractures are to safeguard important intracranial structures, to avoid early and late serious complications, and to reinstate the aesthetic contour

Figure 6



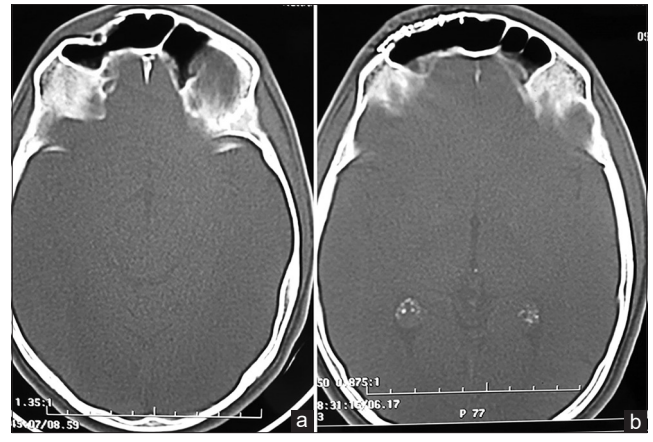
(a) Preoperative view of a patient showing a depressed anterior wall frontal sinus fractures. (b) Postoperative view showing forehead contour deformities were effectively restored with aesthetic results at the incision lines.

of the forehead. Restoration of a normal forehead contour is considered the most important mission to attain in cases of frontal sinus anterior wall fracture. Open reduction and internal fixation via a coronal incision is considered the gold standard for restoration of anterior wall frontal sinus fractures. This approach has various complications like alopecia, long operation time, excessive blood loss, forehead paresthesia, and probability of facial nerve injury. To avoid such complications, endoscopic procedures via a transnasal route, trephine, or a cutaneous forehead incision have been described [6,10,11].

The transnasal endoscopic procedure allows intranasal drainage of the frontal sinus outflow tract with no external scar. Only the fracture situated at the medial part of the anterior frontal sinus wall is reachable; however, the remote laterally and superiorly located fractures are inaccessible. Furthermore, the liability of obstruction of the frontal sinus outflow tract is high with impairment of frontal sinus drainage and ventilation. Steiger *et al.* [6] described an assisted endoscopic anterior wall frontal sinus fracture repair via a trephine approach as an auxiliary procedure for fractures that are situated laterally or medially but not accessible via transnasal route.

The curved course of the frontal sinus outflow tract and complex anatomy with the presence of several important structures around it make the endoscopic surgery of frontal sinus challenging, particularly if the frontal sinus outflow tract is narrow. These anatomical difficulties make transnasal access into frontal sinus cavity to reduce fractured bony segments extremely challenging despite recent instrument and endoscopic technique innovations [12,13]. Hwang and Song [14] treated anterior wall frontal sinus fracture via a stab

Figure 7



(a) Preoperative axial CT scan showing depressed anterior wall frontal sinus fractures. (b) Postoperative axial CT scans showed an excellent anatomic restoration of the frontal sinus contour with normal sinus ventilation and drainage. See the shadow of titanium microplate and screws. CT, computed tomography.

wound on the medial end of the eyebrow. He blindly placed a periosteal elevator to reduce the fractured bony segment to its normal position.

Kim *et al.* [8] assessed the endoscopic technique in a cadaver model and found that endoscopic fracture camouflage with porous polyethylene implant (Medpore Porex Surgical, Newnan, Georgia, USA) with no anatomical reduction was easier and more effective than endoscopic reduction. In our opinion, frontal sinus anterior wall fracture should be treated both functionally and aesthetically. Fracture lines could entangle part of the lining mucosa that could cause mucocele formation if not removed clearly from the fracture sites. Sometimes, displaced frontal sinus anterior wall fractures may be displaced over the posterior wall and if not reduced anatomically, the mucociliary clearance mechanism could be disturbed at the laterally placed remote frontal sinus with its consequences.

Endoscopic-assisted reduction of the anterior frontal sinus wall fractures described in this study is considered a minor invasive procedure with less complication especially when compared with the coronal approach. The forehead incisions are hardly visible especially when located in a skin crease and in older patients. Moreover, it is suitable for patients with a receding hairline. The endoscopic approach offers excellent visualization of the fracture lines and accurate periosteal elevation with minimal soft tissue dissection. Periosteal elevation is made only at the site of location of the microplate and over 1 cm of the adjacent nonfractured frontal bones. The rest of the periosteum over the fracture segments is left attached to bone to aid stabilization of the bony fracture after been reduced.

Operating from the frontal sinus cavity provides an excellent opportunity to evaluate the patency of frontal sinus outflow tract and to take away any separated bony spicules or foreign bodies that may obstruct it. Any entrapped or lacerated mucosa between fracture lines accurately could be removed to avoid mucosal entrapment and late mucocele formation.

Endoscopic reduction of the displaced frontal sinus anterior wall fractures was done completely from sinus cavity with a periosteal elevator to repositioning the bone fragments through the compression phase. One more advantage of using the endoscope is its ability to help an accurate placement of the percutaneous drilling and microscrew placement at the fractured segments (Fig 4,5). Restoring the normal pretrauma anterior-posterior depth of the frontal sinus is essential for a good functioning frontal sinus as the mucociliary mucus blanket is not disturbed by displaced fracture segments and also for protection of the intracranial vital structures as a shock absorbent mechanism.

Fracture reduction of the bony fragments sometimes may be challenging and time consuming, particularly in patient with affection of the superior orbital rim. In four patients, the fracture extended to the superior orbital rim. The three-dimension nature of such fractures and working around corner made the reduction challenging, but with some patience, reduction was succeeded.

## Conclusion

Endoscopic repair of frontal sinus anterior wall fracture with titanium microplate fixation could be done efficiently and safely in selected patients. Contour deformities of forehead were successfully restored and aesthetic results at incision lines were accepted in all patients. Sometimes, reduction and fixation can be relatively hard; however, when compared with coronal approach, endoscopic reduction of frontal sinus anterior fracture is a worthy efficient technique that decreases patient morbidity, operation time, and cost.

## Declaration of patient consent

The authors certify that they have obtained all appropriate patient consent forms. In the form the patient(s) has/have given his/her/their consent for his/her/their images and other clinical information to be reported in the journal. The patients understand that their names and initials will not be published and due efforts will be made to conceal their identity, but anonymity cannot be guaranteed.

## Financial support and sponsorship

Nil.

## Conflicts of interest

There are no conflicts of interest.

## References

- 1 Stong EB, Skyes JM. *Frontal sinus and naso-ethmoid complex fractures. In: PPapel ID. Facial plastic reconstructive surgery. 2<sup>nd</sup> ed.* New York: Thieme Publisher; 2002. 747–758.
- 2 Kalavrezos N. Current trends in the management of frontal sinus fractures. *Injury* 2003; 35:340–346.
- 3 McGraw-Wall B. Frontal sinus fractures. *Facial Plast Surg* 1998; 14:59–66.
- 4 Rodrich RJ, Holler L. The role of the nasofrontal duct in frontal sinus fracture management. *J Craniomaxillofac Trauma* 1996; 2:31–40.
- 5 Gonty AA, Maciani RD, Adomato DC. Management of frontal sinus fractures: a review of 33 cases. *J Oral Maxillofac Surg* 1999; 57:372–379.
- 6 Steiger JD, Chiu AG, Francis DO, Palmer JN. Endoscopic-assisted reduction of anterior table frontal sinus fractures. *Laryngoscope* 2006; 116:1936–1939.
- 7 Strong EB, Kellman RM. Endoscopic repair of anterior table – frontal sinus fractures. *Facial Plast Surg Clin North Am* 2006; 14:25–29.
- 8 Kim K, Mueller R, Huang F, Strong EB. Endoscopic repair of anterior table frontal sinus fracture with a medpor. *Otolaryngol Head Neck Surg* 2007; 136:568–571.
- 9 Shumrick KA. Endoscopic management of frontal sinus fractures. *Facial Plast Surg Clin North Am* 2006; 14:31–35.
- 10 Kim KS, Kim ES, Hwang JH, Lee J. Transcutaneous transfrontal approach through a small peri-eyebrow incision for the reduction of closed anterior table frontal sinus fractures. *J Plast Reconstr Aesthet Surg* 2010; 63:763–768.
- 11 Yoo MH, Kim JS, Song HM, Lee BJ, Jang YJ. Endoscopic transnasal reduction of an anterior table frontal sinus fracture: technical note. *Int J Oral Maxillofac Surg* 2008; 37:573–575.
- 12 Becker SS, Bomeli SR, Gross CW, Han JK. Limits of endoscopic visualization and instrumentation in the frontal sinus. *Otolaryngol Head Neck Surg* 2006; 135:917–921.
- 13 Iro H, Zenk J. A new device for frontal sinus endoscopy: first clinical report. *Otolaryngol Head Neck Surg* 2001; 125:613–616.
- 14 Hwang K, Song YB. Closed reduction of fractured anterior wall of the frontal bone. *J Craniofac Surg* 2005; 16:120–122.