

Initial experience with different transorbital neuroendoscopic approaches

Reda Hussein Kamel,¹ Ahmed El Farouk Abdel Fattah,¹ Ehab Ahmed El-Refaei,² Abdelrahman Younes Ali,¹ Ahmed Afifi³

¹Department of Otorhinolaryngology, Faculty of Medicine, Cairo University

²Department of Neurosurgery, Faculty of Medicine, Cairo University

³ENT Specialist, Kafr El-Sheikh General Hospital, Faculty of Medicine, Cairo University

Correspondence to Ahmed Afifi

³ENT Specialist, Kafr El-Sheikh General Hospital, Faculty of Medicine, Cairo University

E-mail: mokhtaratsalafyah5@gmail.com
Tel: 01066641324

Pan Arab Journal of Rhinology
2019, 10:2-8

Objective: This study aimed to present our initial experience to evaluate the feasibility of the different transorbital endoscopic approaches as an adjuvant technique to endoscopic transnasal approach of the skull base and to evaluate the safety and efficacy of these approaches.

Background: Although endonasal approaches are highly expanded, they have limitations in dealing with some skull base lesions, including the inability to perform microsurgical dissection with complex lesions, access to the anterior cranial fossa laterally over the orbits away from the midline, and limited working space when multiple surgeons are working. The orbits appear to offer an excellent portal for endoscopic access to the skull base and adjacent craniofacial regions. Operating through the orbits might eliminate some of the challenges of the currently used transnasal approaches.

Materials and Methods: This study was conducted on 10 sides of dry skulls and 10 sides of fresh frozen cadavers for application of the new approach of transorbital neuroendoscopic surgery.

Results: Anatomical orientation of the orbit, skull base and adjacent craniofacial region appeared very easy during transorbital endoscopic dissection on the dry skull first then during our meticulous dissection on frozen cadavers. We expected no major complications should happen to patients underwent to TONES.

Conclusion: All transorbital endoscopic approaches to skull base are feasible, direct, effective and expected to be safe surgery. However, we need to conduct these approaches on life patients starting with minimal pathology as complicated sinusitis, fibro-osseous lesions and C.S.F. leak.

Keywords: Transorbital, superior eye lid crease, lateral retrocanthal, precaruncular, anterior cranial fossa, middle cranial fossa, temporal fossa.

Pan Arab Journal of Rhinology 2019, 10:2-8

Introduction

Different skull base lesions may arise from the bones of the skull base itself or involve it from above (intracranially), or from below (the sinonasal cavity and orbits). [1]

Meningioma is the most common skull base lesion that may also affect the optic apparatus vulnerable to compression and ischemia. [2] While the most common benign tumors involving the anterior skull base from below are inverted papillomas and juvenile angiofibromas. [3] Malignant sinonasal tumors such as squamous cell carcinoma, adenocarcinoma, esthesioneuroblastoma, lymphoma, melanoma and undifferentiated carcinomas also may involve the skull base. [4] Less commonly, orbital tumors such as lacrimal gland neoplasms, neurogenic tumors, lymphomas and rhabdomyosarcomas may involve the skull base also. [3]

Numerous craniofacial approaches such as frontotemporal sphenoidal craniotomy, extended bifrontal craniotomy, transfacial have been developed to address the anatomic challenges of approaching the skull base. [5]

Endoscopic approaches have significantly reduced the morbidity of open surgical procedures and have, in selected cases, been shown to be as effective as traditional open techniques or better. [6]

Although endonasal approaches have reduced the morbidity of accessing pathology in the nasal cavity and appear to have benefits over traditional open approaches but they have

limitations in dealing with some circumstances, including the inability to perform microsurgical dissection with complex lesions, adequate dural closure, access to the anterior cranial fossa laterally over the orbits away from the midline, and limited working space when multiple surgeons are working. [7]

The orbits appear to offer an excellent portal for endoscopic access to the skull base and adjacent craniofacial regions. The orbital roof is thin, a craniotomy is rapidly and easily accomplished, reconstruction is straightforward, and brain retraction is limited. Operating through the orbits might eliminate some of the challenges of the current used transnasal approaches. [8]

So in this study, we present our initial experience to evaluate the feasibility of the different transorbital endoscopic approaches as an adjuvant technique to endoscopic transnasal approach of the skull base and to evaluate the safety and efficacy of these approaches.

Materials and Methods

The present study was conducted on 10 sides of dry skulls and 10 sides of fresh frozen cadavers for application of the new different transorbital endoscopic approaches to the skull base. Dry skulls and frozen cadaveric specimens were dissected in the Cairo University and the Military Medical Academy.

Bilateral transorbital and transnasal endoscopic approaches

to skull base were done.

Dry skulls used for endoscopic assessment of all orbital walls, suture lines, fissures and foramina. Reaching anterior, middle cranial fossa and temporal fossa through the orbit.

While the fresh frozen cadavers used for applying the different transorbital endoscopic dissections as Superior eyelid crease (SLC), Lateral retrocanthal (LRC), Precaruncular (PC) and Preseptal lower eyelid (PS).

The results were analyzed using descriptive statistical methods and SPSS 17.0.

Results

Anatomical orientation of different foramina, suture lines, orbital walls and different endoscopic landmarks through the orbit was the cornerstone in our study and we found it was easy to start the dissection on the dry skulls.

We divided the orbit with two imaginary lines into 4 quadrants; superior, inferior, medial and lateral quadrants (Fig. 1).

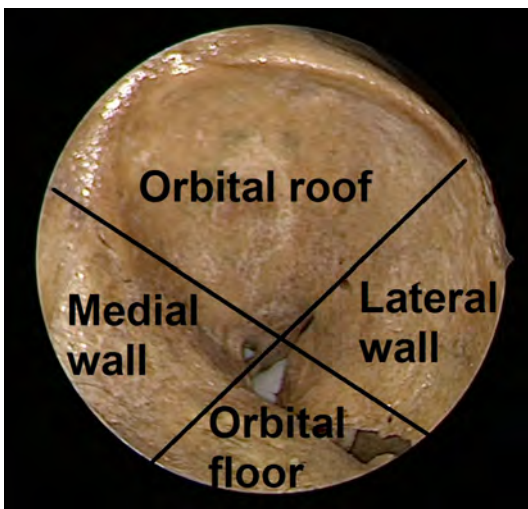


Fig 1: Overall endoscopic view of the left orbit of a dry skull showing two imaginary lines divided the orbit into four quadrants: superior (roof), inferior (floor), medial and lateral walls.

One of the most important suture lines within the orbit is called the sphenofrontal suture which separates the anterior cranial fossa (anteriorly) from middle and temporal fossa (posteriorly). The second one is called frontoethmoidal suture between the frontal bone and the ethmoid bone and it's our medial limit through the approach to anterior cranial fossa (Fig. 2).

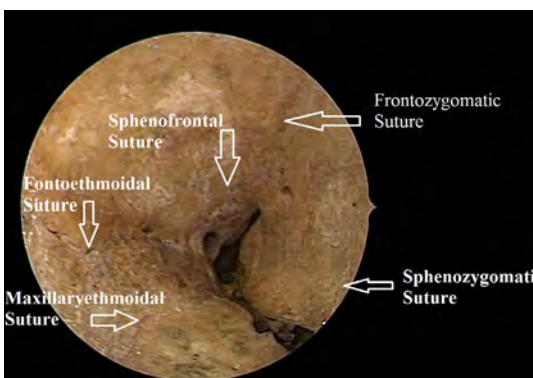
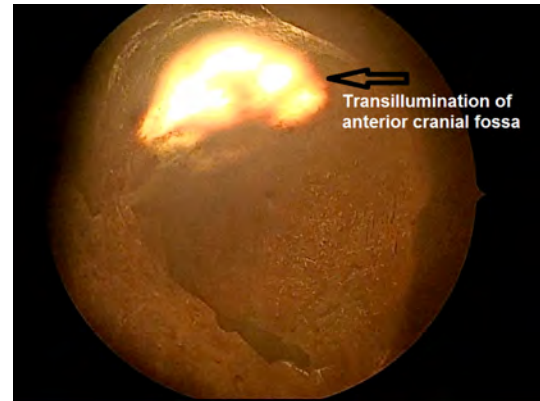
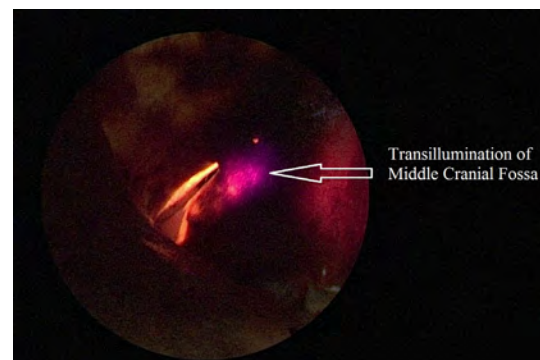


Fig 2: Suture lines within the orbit.

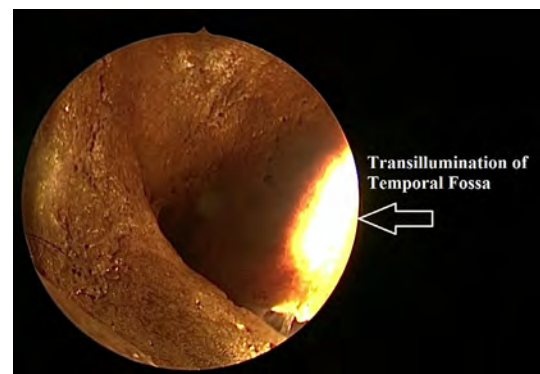
In our dissection, we used transillumination from above to illuminate the anterior cranial fossa, from behind to illuminate the middle cranial fossa and laterally to illuminate the temporal fossa. To know our limits of each approach as an example; the middle cranial fossa is only transilluminated at the area between the superior and inferior orbital fissures so drilling through this area is safe to reach middle cranial fossa which is approximately 173 mm² while drilling lateral to this area is safe to reach the temporal fossa (Figs. 3-4).



A

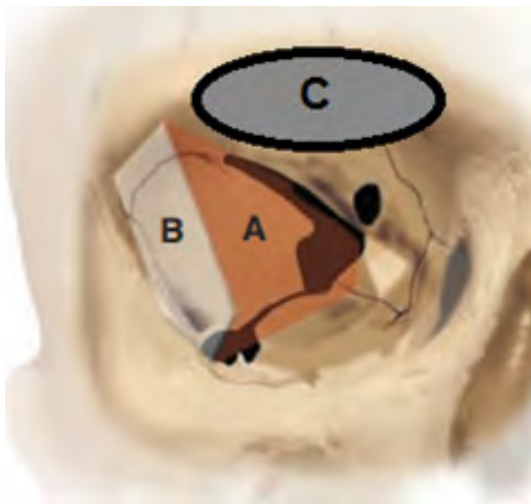


B




C

Fig 3: (a) Transillumination through Anterior cranial fossa (b) Middle cranial fossa (c) Temporal fossa.



1



2

Fig 4: (1) Diagram showing right orbital socket with the different sites of skull base approach (a) For middle cranial fossa approach (b) For temporal fossa approach (c) For anterior cranial fossa approach (2) Left orbital socket after drilling between both orbital fissures to reach middle cranial fossa.

There are many foramina within the orbit: we found a single anterior ethmoidal foramen in all specimen which was located approximately 20 mm posterior to the lacrimal bone while the posterior ethmoidal was not a single foramen like the anterior ethmoidal foramen but it might be two or three foramina. In our study, commonly they are two foramina occupying the divided posterior ethmoidal arteries and they are located 10 mm posterior to the anterior ethmoidal foramen. The optic canal located approximately 6 mm posterior to posterior ethmoidal foramina. The superior orbital fissure which was laterally presented and could be reached from superior and lateral approaches. It occupied V1 (ophthalmic nerve), Cranial nerves III, IV, VI, and the superior ophthalmic vein. While the inferior orbital fissure inferiorly presented and it occupied two main openings; the foramen rotundum for V2 (Maxillary nerve) and the pterygomaxillary fissure for the internal maxillary artery. Another important foramen was the foramen for recurrent meningeal artery, which should be identified and cauterized for fearing of bleeding specially during lateral trans orbital endoscopic approach, this foramen is not commonly described in literature for the orbital anatomy but endoscopically, we found this foramen approximately in all dry skulls which we dissected. It was

located approximately 6 mm lateral to superior orbital fissure with 6.7 mm Mean and 0.537 Standard Deviation (SD) : while it lies approximately 27.5 mm from the lateral orbital rim with 27.5 mm Mean and 0.66 SD (Fig. 5).

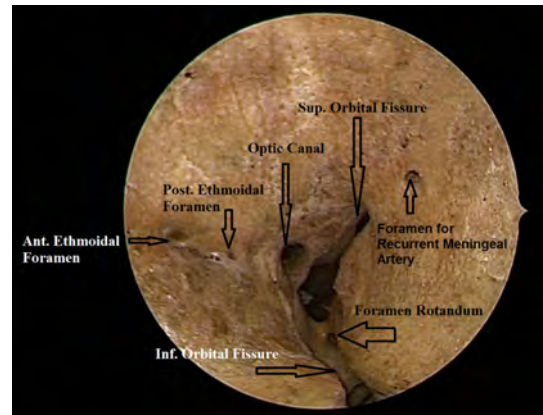
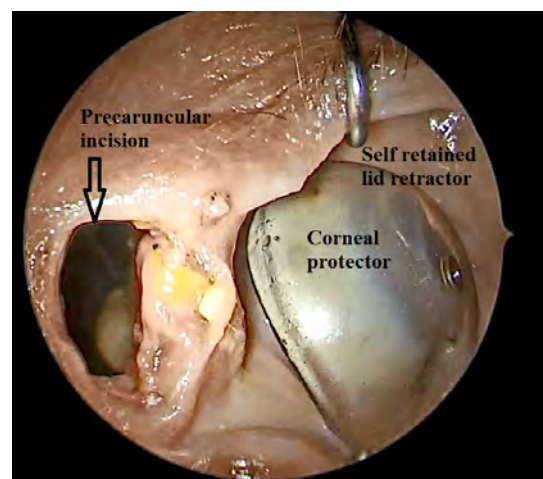


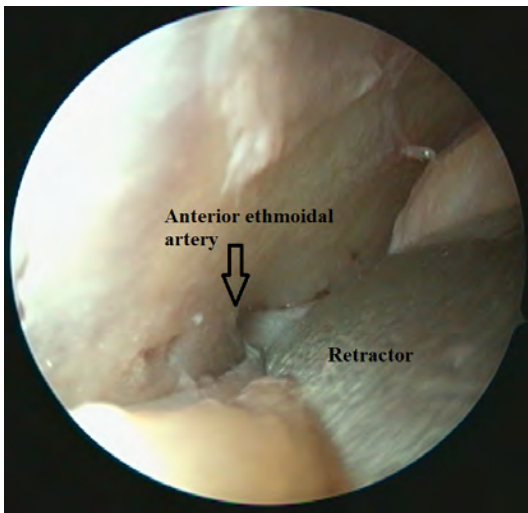
Fig 5: Left orbital socket showing different fissures and foramina within the orbit.

Then, fresh frozen cadavers were used to apply three endoscopic transconjunctival approaches as the precaruncular approach (PC) to reach medial quadrant, lateral retrocanthal approach (LRC) to reach lateral quadrant and inferior preseptal approach (PS) to reach orbit floor and one external approach through the superior lid crease (SLC) to reach orbital roof.

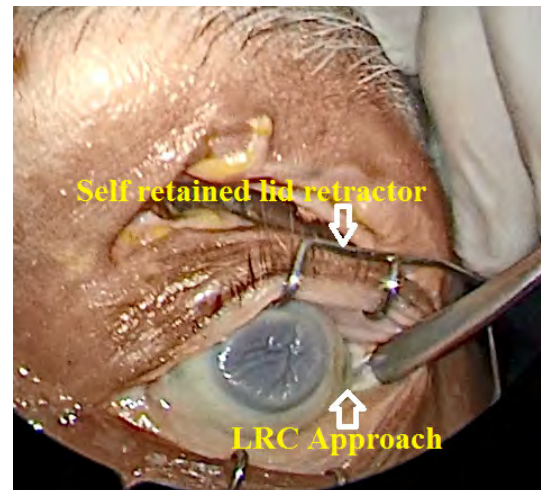
For PC approach, we applied the corneal protector, doing incision between the skin and the conjunctiva medial to the caruncle then dissect the conjunctiva superiorly and inferiorly. Retract the upper and lower eyelid using self retained lid retractor. Using malleable retractor to retract the globe (extraconal) laterally. After reaching the medial orbital rim using sharp incision, then elevate the periosteum with periosteal elevator. At this point we can use the 0 degree endoscope and retract the whole globe laterally reaching the anterior ethmoidal artery at 20 mm posterior to the orbital rim (we can do bipolar cautery and cut it) then after 10 mm posteriorly we reached the posterior ethmoidal artery then after 6 mm the optic nerve. We can use this approach as an alternative approach for transnasal approach to reach lesions such as fibro-osseous tumor lateral to lamina papyracea, ligation of anterior or posterior ethmoidal arteries and optic nerve decompression (Fig. 6).



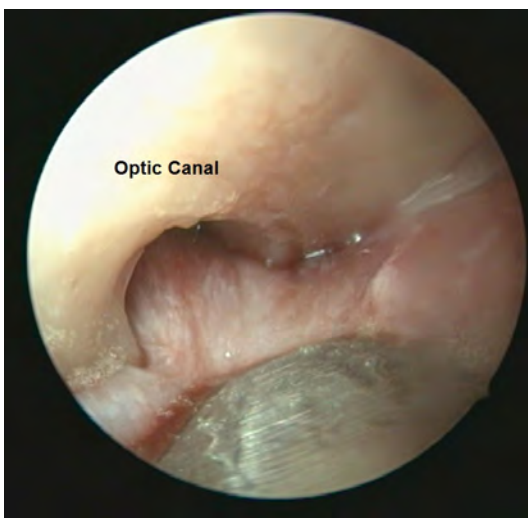
A



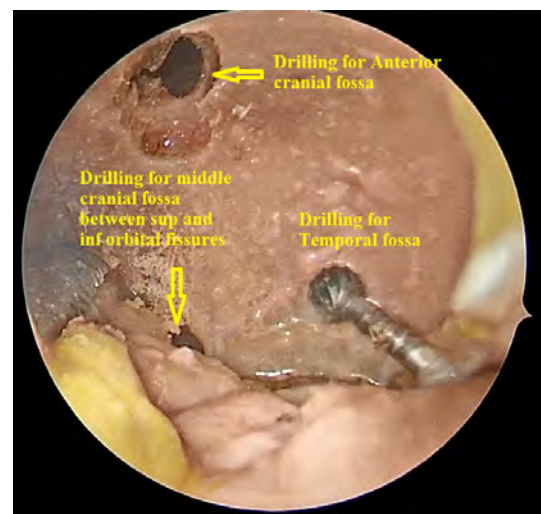
B



A



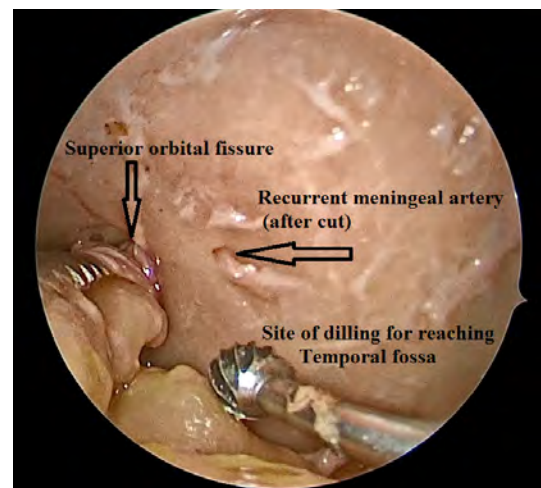
C



B

Fig 6: (a) Incision for precaruncular approach (b) Identification of anterior ethmoidal artery (c) Identification of optic nerve.

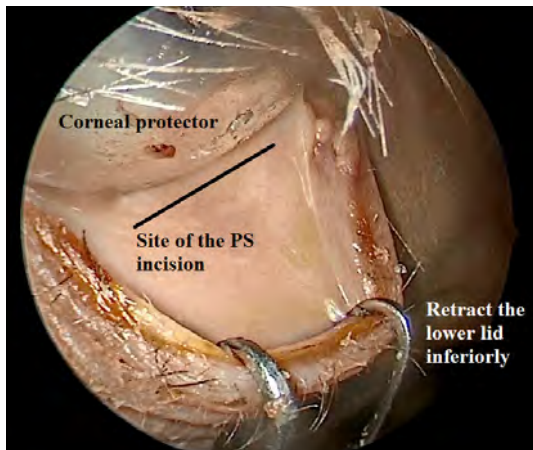
For LRC approach, we applied the corneal protector, doing vertical lateral conjunctival incision then retract the lateral canthal tendon. Sharp incision at the lateral orbital rim then elevate the perisoteum. At this point we can use the 0 degree endoscope and retract the whole globe medially reaching sphenozygomatic suture and continuing the dissection till reaching the recurrent meningeal artery through its canal and do cauterization to the artery. Dissection is continued till reaching superior orbital fissure (medially). Identifying sphenofrontal and frontozygomatic suture is very important. Drilling posterior to the sphenofrontal suture and use Kerrison punch forceps to remove a part of the greater wing of the sphenoid bone (between the superior and inferior orbital fissures) to show the dura of the middle cranial fossa. If we drill at the lateral part of the greater wing of sphenoid (lateral to the area between superior and inferior orbital fissures) we approach the temporal fossa (Fig. 7).



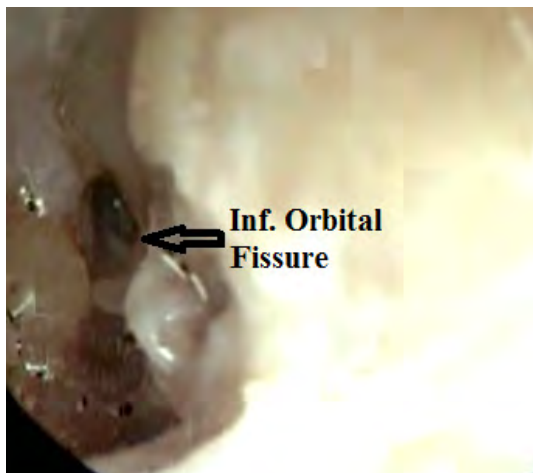
C

Fig 7: (a) Incision for lateral retrocanthal approach (b) Drilling posterior to sphenofrontal suture and site of drilling to reach middle cranial fossa and temporal fossa (c) Site of drilling for reaching temporal fossa and site of recurrent meningeal artery.

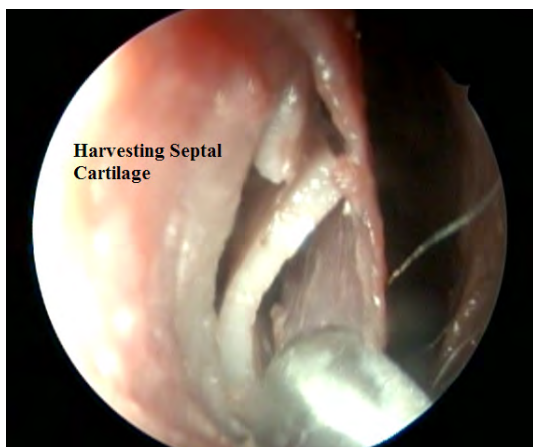
For PS approach, we applied the corneal protector and retract the lower eyelid, we perform conjunctival incision 6 mm inferior to the rim of lower eyelid then extend the conjunctival incision medially and laterally. After reaching the inferior orbital rim using a sharp incision we elevate the periotome with periosteal elevator (preseptally). Dissection is carried out posterior to orbicularis oculi muscle. At this point we can use the 0 degree endoscope and retract the whole globe superiorly reaching the inferior orbital fissure. Through this approach we could repair of infra orbital wall fracture, manage any neoplasm originating or extending to the lower part of the globe and manage pathology related to V2 (Fig. 8).



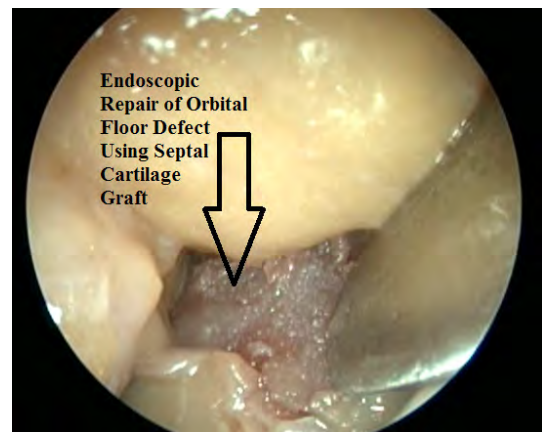
A



B



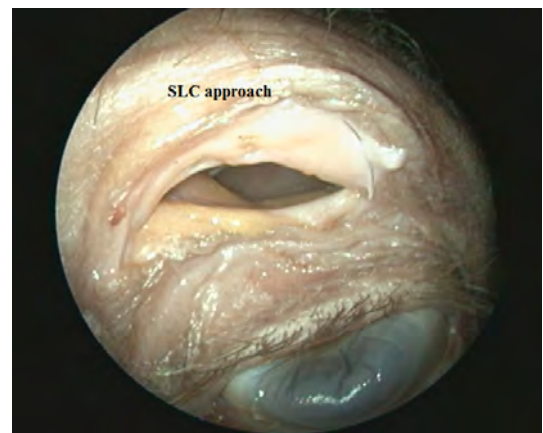
C



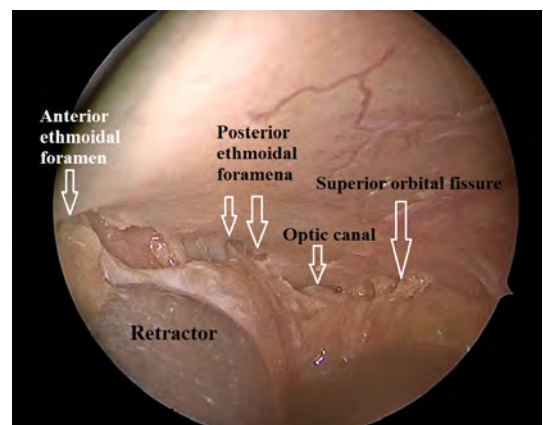
D

Fig 8: (a) Incision for inferior preseptal approach (b) Identification of the inferior orbital fissure (c) Harvesting septal cartilage (d) Endoscopic repair of orbital floor defect.

For SLC approach, we applied the corneal protector, doing skin incision at the superior lid crease of the upper eyelid, the cut done through the skin and orbicularis oculi muscle then elevation of myocutaneous flap superiorly, till reaching superior orbital rim then elevate the periotome. At this point we can use the 0 degree endoscope and retract the globe inferiorly with a malleable retractor (extraconal) dissect posteriorly till reaching sphenofrontal suture and identifying anterior and posterior ethmoidal artery foramina (medially), optic canal and superior orbital fissure (posteriorly). Drilling anterior to the sphenofrontal suture and use Kerrison forceps to remove a part of the frontal bone to show the dura of the anterior cranial fossa (Fig. 9).



A



B

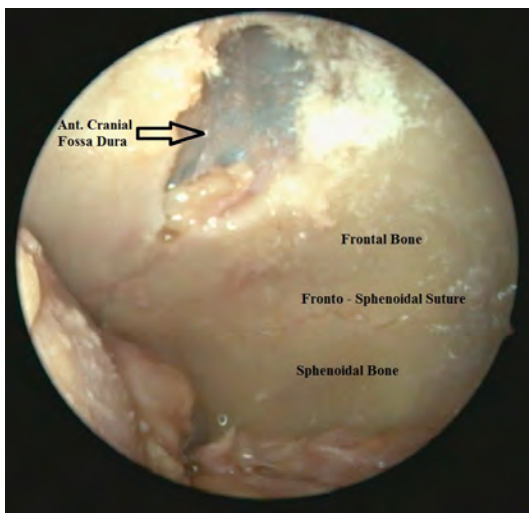


Fig 9: (a) Incision for superior lid crease approach (b) Identification of ethmoidal foramina, optic canal and superior orbital fissure (c) Drilling of frontal bone anterior to the sphenofrontal suture to reach dura of anterior skull base.

Discussion

The transconjunctival approach to the orbit was described more than a century ago by Bourguet for the aesthetic repair of eyelid defects. [9] Few studies in literature discuss the transorbital endoscopic approach to the skull base. Moe et al, publish papers using these new approaches in life patients to repair CSF leak, sinogenic complication of orbit and skull base and other benign skull base lesions. [8,10,11] In our study, we believe that anatomical orientation is the first step to perform this new approach so we did our dissection on dry skulls and fresh frozen cadavers.

In the literature, there is no one of the skull base surgeon did his dissection study first on dry skulls, and we found that it was very important, specially for the beginners to be oriented with the different landmarks such as orbital walls, suture lines, foramina and fissures.

Roughly we divided the orbit into four quadrants superior (roof), inferior (floor), medial and lateral walls. These four corridors described also with Moe et al. [8]

In our dissection we use transillumination from above to illuminate the anterior cranial fossa anterior to sphenofrontal suture, from behind to illuminate the middle cranial fossa and from the lateral part to illuminate temporal fossa.

To approach middle cranial fossa, we should drill posterior to sphenofrontal suture on the greater wing of sphenoid bone between superior and inferior orbital fissures as described with Moe and Ellenbogen. [11] To approach the temporal fossa, we should drill the greater wing lateral to the area between both orbital fissures.

In our study, We found that the anterior ethmoidal foramen in all specimens is single and located approximately 20 mm posterior to the lacrimal bone while there are two foramina occupying the divided posterior ethmoidal arteries and they are located 10 mm posterior to the anterior ethmoidal foramen. The optic canal located approximately 6 mm posterior to posterior ethmoidal foramina. These dimensions were conducted also with the study of Moe et al. [8]

Another foramen which is called foramen for recurrent

meningeal artery, this foramen is not commonly described in academic studies for the orbital anatomy. But endoscopically, we found this foramen approximately in all dry skulls which we dissected. It's located approximately 6 mm lateral to superior orbital fissure and at a distance of approximately 28 mm from the lateral orbital rim. The lacrimal artery travels superolaterally along the upper border of the lateral rectus to supply the lacrimal gland. It gives off zygomatic and lateral palpebral branches and anastomosis with the middle meningeal artery via the recurrent meningeal artery. [12]

Frozen cadavers endoscopic dissection:

Lateral corridor (LRC approach) is the important transorbital endoscopic approach to manage pathology within middle cranial and temporal fossa because we can do dissection of the pathology without crossing vital structures such as optic nerve or ophthalmic artery. In contrast, although endonasal approaches are highly expanded, they have limitations in dealing with some skull base complex lesions, access to the anterior cranial fossa laterally over the orbits, and limited working space when multiple surgeons are working. [7]

Through this approach we can easily reach and ligate the recurrent meningeal artery and do good hemostasis before we access the deep lateral orbit, lateral aspect of the frontal fossa, middle cranial fossa, or temporal fossa. [8] Drilling of lateral and posterior orbital walls may take time because of the thickness of these orbital walls. This fact also described by C Rene . [12]

We can use this approach not only for the removal of pathology confined to the middle cranial or temporal fossa, also we can use it to do the reconstruction for congenital defect in skull base as congenital absence of the greater wing of sphenoid in neurofibromatosis, which may result in pulsatile proptosis owing to orbital encephalocele [13] and also we can use this approach to do orbital decompression. [14]

Superior corridor (SLC approach) is providing an easy, rapid, a vascular and cosmetic approach to manage the anterior cranial fossa and orbital roof lesions. We should do our dissection subperiosteally at the superior orbital rim at lateral 2/3 for fearing of injure supratrochlear or supraorbital bundles. [12]

Dissection should be done till expose all foramina from medial to lateral: the anterior, posterior ethmoidal foramina, optic canal, superior orbital fissures and the canal for recurrent meningeal artery. We can do devascularization of the tumour through ligation of the anterior and posterior ethmoidal arteries. Our drilling to anterior cranial fossa should be limited with sphenofrontal suture posteriorly, frontoethmoidal suture medially and frontozygomatic suture laterally. Drilling of the orbital roof is very easy and the bone is not thick as the lateral orbital wall and not very strong as described by C Rene . [12]

The SLC approach is used for orbital roof fractures, pathology of the frontal sinus (including posterior wall fractures with CSF leak), and anterior cranial fossa lesions. [8] If we need to enter the frontal sinus through this approach, it is mandatory to use neuronavigation because there are no obvious bony landmarks within the orbital roof to know the extension of the frontal sinus.

Medial corridor (PC approach) is providing a direct and a vascular approach to the medial region of the orbit and heals rapidly without scarring. [10]

We can do devascularization of the tumor by cauterization

of the anterior and posterior ethmoidal arteries. Then we continued the dissection till the optic nerve. [8,15]

The PC approach is one of the difficult approach we use in this study because of fearing to do harmful trauma to the lacrimal apparatus. Some authors as Moe et al., used lacrimal probes in the lacrimal canaliculi to prevent the inadvertent transection of the canaliculi and also aid in the retraction superiorly and inferiorly. [8]

The PC approach alone or in combination with the endoscopic trans-nasal approach is used to manage pathology originate from the medial part of the globe or pathology extended from the nose and paranasal sinus to the medial part of the globe as in cases of fibro-osseous lesions, ethesanioblastoma, fracture skull base, complicated sinusitis medial cavernous sinus lesions, cavernous carotid arteries and optic nerve decompression. [8,16]

The medial orbital wall is very weak, so it can be easily fractured during elevation of periosteum. The medial bone to the optic nerve is hard so we can use a diamond bur with a suitable irrigation not to do iatrogenic trauma or thermal injury to the nerve. Balakrishnan and Moe say it is better to do decompression by out-fracturing rather than by drilling, which can cause thermal injury to the nerve. [15]

Inferior corridor (PS approach) has the advantage of preventing orbital fat from herniating into the surgical field. [8]

The PS approach is the easiest approach to reach the inferior orbital fissure and we found that the inferior orbital wall is very delicate and easily fractured during dissection so delicate manipulation is recommended during this approach specially at the medial part of the orbital floor (the side we can do orbital decompression). [12] We should take care also during periosteal incision at the lower orbital rim from injuring of the infra orbital nerve and our landmark is the bulge of the infraorbital canal at the orbital floor.

We can use this approach to reach the foramen rotundum, neoplasms or trauma that include the maxillary sinus or orbital floor and orbital decompression as described by Moe et al. [8]

Management of different pathologies of the anterior, middle cranial fossae and temporal fossa has been demonstrated using these approaches. The technique provides coplanar pathway to the target and limits the requirement for angled endoscopy that could be visually disorienting to some surgeons. Moreover, it offers a favorable trajectory for accessing the lateral frontal sinus, orbit, and anterior cranial base that may be lacking in transnasal approaches. [8]

Conclusion

Orbit is a new and easy access to many sites of the skull base specially lesions located lateral to the optic nerve. Our anatomical orientation of the orbit, anterior, middle cranial fossae and temporal fossa suggest that this technique is effective, allowing the surgeon to achieve operative goals for different pathologies.

References

1. Borges A. Skull base tumours: Part I. Imaging technique, anatomy and anterior skull base tumours. *Eur J Radiol.* 2008;66(3):338-347.

2. Hentschel SJ, Vora Y, Suki D et al. Malignant tumors of the anterolateral skull base. *Neurosurgery.* 2010;66(1):102-112.
3. Kaplan MJ, Fischbein NJ, Harsh GR. Anterior skull base surgery. *Otolaryngol Clin North Am.* 2005;38(1):107-131.
4. Jethanamest D, Morris LG, Sikora AG. Esthesioneuroblastoma: A population-based analysis of survival and prognostic factors. *Arch Otolaryngol Head Neck Surg.* 2007;133(3):276-280.
5. Raza SM, Conway JE, Li KW, Attenello F, Boahene K, Subramanian P, Quinones-Hinojosa A. A modified frontal-nasal-orbital approach to midline lesions of the anterior cranial fossa and skull base: technical note with case illustrations. *Neurosurg Rev.* 33:63-70, 2010.
6. Nicolai P, Battaglia P, Bignami M, et al. Endoscopic surgery for malignant tumors of the sinonasal tract and adjacent skull base: a 10-year experience. *Am J Rhinol.* 2008;22(3):308-316.
7. Snyderman CH, Carrau RL, Kassam AB, Zanoletti A, Prevedello D, Gardner P, Mintz A. Endoscopic skull base surgery: principles of endonasal oncological surgery. *J Surg Oncol* 2008, 97:658-664.
8. Moe KS, Bergeron CM, Ellenbogen RG. Transorbital neuroendoscopic surgery. *Neurosurgery.* 2010;67:16-28.
9. Bourguet J. Les hernies graisseuses de l'orbite. Noire traitement chirurgical. *Bull Acad Med Paris.* 1924;92:1270-1272.
10. Moe K. The precaruncular approach to the medial orbit. *Arch Facial Plast Surg.* 2003;5(6):483-487.
11. Moe KS and Ellenbogen RG. Transorbital endoscopic approaches to the middle cranial fossa. *Master techniques in otolaryngology, skull base surgery, Ch 34,* Myers EN, Snyderman I and Gardner PA, Wolters Kluwer. 2015;343-356.
12. C Rene ´. Update on orbital anatomy. *Eye.* 2006;20:1119-1129.
13. Clauser L, Carinci F, Galie M. Neurofibromatosis of the orbit and skull base. *J Craniofac Surg.* 1998;9:280-284.
14. Sellari-Franceschini S, Lenzi R, Santoro A, et al. Lateral wall orbital decompression in Graves' orbitopathy. *Int J Oral Maxillofac Surg.* 2010;39:16-20.
15. Balakrishnan K and Moe KS. Applications and Outcomes of Orbital and Transorbital Endoscopic Surgery. *American Academy of Otolaryngology—Head and Neck Surgery.* 2011;144(5):815-820.
16. Lim JH, Sardesai MG, Ferreira M, Moe KS. Transorbital Neuroendoscopic Management of Sinogenic Complications Involving the Frontal Sinus, Orbit, and Anterior Cranial Fossa. *J Neurol Surg B.* 2012;73:394-400.