

# Contralateral outcome in unilateral allergic fungal rhinosinusitis: impact on patient management and counseling

Osama A. Marglani,<sup>a,b</sup> Reda Kamel,<sup>c</sup> Islam R. Herzallah,<sup>b,d</sup> Ahmed M. Shaikh<sup>b</sup>

<sup>a</sup>Department of Otolaryngology Head and Neck Surgery, Umm Al-Qura University, Makkah, Saudi Arabia

<sup>b</sup>ENT, Head and Neck and Skull Base Center, King Abdullah Medical City (KAMC-HC), Makkah, Saudi Arabia

<sup>c</sup>Department of Otolaryngology–Head and Neck Surgery, Faculty of Medicine, Cairo University, Egypt

<sup>d</sup>Department of Otorhinolaryngology–Head and Neck Surgery, Faculty of Medicine, Zagazig University, Egypt

Corresponding author:

Islam R. Herzallah, Department of Otorhinolaryngology – Head and Neck Surgery, Faculty of Medicine, Zagazig University, Zagazig, Egypt

E-mail: iherzallah@gmail.com

**Pan Arab Journal of Rhinology Journal**  
2017, 7:1-6

**Aim:** Allergic fungal rhinosinusitis (AFRS) is a distinct clinical and pathological entity. Various recurrence rates have been reported in literature, but the contralateral disease development in unilateral AFRS cases has not been specifically investigated. The aim of the current study was to analyze the outcomes in unilateral cases of AFRS.

**Setting and design:** This is a retrospective analysis conducted at a tertiary care institution.

**Patients and methods:** We have conducted a retrospective review of all patients who underwent endoscopic sinus surgery from January 2012 to March 2015 at our institution. AFRS patients' demographics, diagnosis, management, and follow-up data were collected.

**Statistical analysis:** Analyses were performed using IBM SPSS 22.0 for Windows. The prevalence of AFRS and unilateral AFRS was calculated. In case of unilateral AFRS, further descriptive analysis was performed.

**Results:** AFRS was diagnosed in 52 (38.2%) out of 136 cases of chronic rhinosinusitis with or without nasal polyps treated with endoscopic sinus surgery. Out of the 52 AFRS patients, 16 (30.8%) cases presented with unilateral AFRS, and all were treated with standard surgical and medical therapy. During a mean follow-up of 24.8 months, nine (56.2%) of the 16 unilateral cases remained disease-free, four (25%) developed AFRS on the contralateral side, two (12.5%) had recurrent ipsilateral AFRS, and one (6.25%) had both ipsilateral recurrence and contralateral development of AFRS.

**Conclusion:** Postoperative development of contralateral disease in unilateral AFRS cases is not uncommon, and it frequently occurs even without involvement of the originally operated side. These findings require special attention in patients' management, follow-up, and counseling.

**Keywords:** bilateral disease, chronic sinusitis, contralateral development, endoscopic sinus surgery, follow-up, laterality, predominant nasal polyps, prevalence, recurrence rate, sinonasal polyposis

Pan Arab Journal of Rhinology Journal 2017, 7:1-6

## Introduction

Allergic fungal rhinosinusitis (AFRS) is a noninvasive form of fungal chronic rhinosinusitis (CRS) with distinct clinical and pathological findings and a high tendency for recurrence. [1–4] The first description of this disease comes from the observation of McCarthy and Pepys in 1971, [5] when they reported a patient with allergic bronchopulmonary aspergillosis having associated sinonasal disease. In 1981, Miller et al. described the condition as 'allergic aspergillosis of paranasal sinuses', a disease entity similar to allergic bronchopulmonary aspergillosis. [6] In 1983, Katzenstein et al. first isolated the allergic mucin and termed this disease as allergic fungal sinusitis, [7] which is now better known as AFRS. [8–10] Since its description, this disease entity has been extensively studied but continues to pose challenges in diagnosis and management. [11–13]

Over the years, various diagnostic criteria have been proposed for diagnosis of AFRS, out of which the criteria described by Bent and Kuhn [14] are widely accepted. The following major criteria were proposed for diagnosis: (a) type 1 (IgE-mediated) hypersensitivity reaction; (b) nasal polyposis; (c) characteristic computed tomography (CT) scan finding; (d) eosinophilic mucin; and (e) positive fungal culture or smear. The percentage of strictly unilateral AFRS varies in literature, and was reported to be more or less

common than bilateral disease. [2,15,16]

Unilateral AFRS seems to be a challenging pathology to understand; if AFRS represents only an allergic reaction, then unilateral AFRS should hardly exist [9,17,18]. In addition, despite the advancement in medical and surgical strategies, recurrence in AFRS in general poses another challenging problem with reported incidence that eventually can reach more than 60%. [19,20]

The objective of this study was to analyze the contralateral outcome pattern in unilateral AFRS cases, a matter that, to the best of our knowledge, has not been specifically investigated in literature before. This information may have an impact on patients' counseling, management, and/or follow-up.

## Material and Methods

After obtaining Institution Review Board approval at our institution, we conducted a retrospective review of all patients who underwent endoscopic sinus surgery (ESS) for CRS with or without nasal polyps from January 2012 to March 2015. All patients' demographics, diagnosis, management, and follow-up data were retrospectively collected. In this study, patients diagnosed with

unilateral AFRS were particularly analyzed. All patients who had a history of previous sinonasal surgery were excluded.

### Diagnosis of allergic fungal rhinosinusitis

Patients were diagnosed with AFRS upon fulfillment of the five Bent and Khun criteria, namely (a) type 1 hypersensitivity reaction to fungal antigens; (b) nasal polyposis; (c) characteristic CT scan findings including hyperdense areas; (d) eosinophilic mucin; and (e) positive fungal smear or culture.

Unilateral AFRS cases included those patients diagnosed according to Bent and Khun criteria and who had strictly unilateral involvement of the paranasal sinuses with the contralateral side completely disease-free.

### Endoscopic and computed tomography findings

Polyps were assessed endoscopically based on Meltzer's et al. [21] endoscopic grading system of nasal polyposis: grade 0, no visible polyps; grade 1, smallest-size polyps confined within the middle meatus; grade 2, polyps occupying the middle meatus; grade 3, polyps extending beyond the middle meatus into the nasal cavity, but not reaching below the inferior edge of the inferior turbinate; grade 4, polyps filling up the nasal cavity.

In addition to the hyperdense areas on paranasal sinus CT scan as part of the definition and inclusion criteria, Lund-Mackay CT scores and bony erosions were also documented.

### Treatment and follow-up protocol for allergic fungal rhinosinusitis

All AFRS patients were treated with preoperative oral steroids followed by ESS with wide sinusotomies. We have a protocol of giving oral steroids for 7 days before surgery (0.5 mg/kg of prednisolone), and to continue it postoperatively in tapering doses for 6–8 weeks (40 mg for 4 days, 30 mg for 4 days, 20 mg for 1 week, followed by 10 mg for 2–4 weeks). We also supplement it with budesonide nasal irrigations (twice-daily irrigations with 1 mg of budesonide mixed with 240 ml of saline solution). Once the oral steroids are tapered, all patients were maintained on budesonide irrigations on the diseased sides.

After the initial weekly postoperative follow-up period, patients were followed up monthly for the first 6 months and then once in 3 months thereafter. On each follow-up visit, nasal endoscopy was carried out to monitor any disease development. Boosts of short-course oral steroids were given in cases with early detection of polyps. In cases of persistent disease reported during follow-up, we have recorded the side of the pathology (ipsilateral, contralateral, or both) and the time of presentation with recurrent disease or contralateral AFRS based on endoscopic and CT findings.

### Statistical analysis

Statistical analyses were performed using IBM SPSS 22.0 for Windows (IBM Corp., Armonk, New York, USA). The significance level was set at  $P$  greater than 0.05. The prevalence of AFRS and unilateral AFRS was calculated. In unilateral AFRS, we have performed descriptive analysis of age, sex, endoscopic grades, CT scores, duration of follow-up, outcome, and time of presentation with recurrent or contralateral AFRS. Although outside the focus of this study, recurrence rate in bilateral AFRS was also documented and compared with that of unilateral disease.

### Results

A total of 136 CRS cases with or without nasal polyps were managed by ESS at our institution over the studied time frame. Out of these, 52 (38.2%) patients were diagnosed with AFRS. After complete clinical and radiological evaluation,

16 (30.8%) AFRS cases were diagnosed as unilateral AFRS with the contralateral side completely disease-free (Fig. 1a). Out of the 16 unilateral AFRS cases, 12 (75%) patients were female and four (25%) were male. Age of presentation ranged from 18 to 50 years, with a mean±SD of 32.8±10.4 months. Mean±SD follow-up time was 24.8±9.8 months, with a range of 12–44 months.

### Preoperative endoscopic and computed tomography findings in unilateral allergic fungal rhinosinusitis cases

Preoperative polyp grades had a mean±SD of 3.0±0.44. Preoperative Lund-Mackay scores had a mean±SD of 9.81±1.87. Bone erosions were detected in seven (43.8%) cases: six cases with lamina papyracea erosion, and one case with both lamina papyracea and skull base involvement.

### Outcomes in unilateral allergic fungal rhinosinusitis

Out of the 16 unilateral AFRS cases reviewed, nine (56.2%) patients remained free of disease during the follow-up period, four (25%) patients had contralateral development of AFRS (Fig. 1), two (12.5%) had ipsilateral recurrence of disease, and one (6.25%) suffered from both ipsilateral recurrence and contralateral development of AFRS (Table 1 and Fig. 2). Therefore, a total of five (31.3%) patients had contralateral development of disease, whereas three (18.8%) patients had ipsilateral recurrence.

Although the occurrence of AFRS in the contralateral (nonoperated) side was higher than ipsilateral recurrence (31.3 vs. 18.8%), the difference was not statistically significant ( $P=0.41$ ). Overall, 43.8% of patients required another surgery for their recurrence and/or contralateral AFRS. This pattern of recurrence and outcome is presented in Table 1 and Fig. 2.

The time at which patients presented with contralateral development of AFRS ranged from 6 to 29 months postoperatively (mean±SD: 15±9.3 months). Time of presentation with ipsilateral recurrence ranged from 13 to 24 months (mean±SD: 17.7±5.7 months).

### Postoperative endoscopic and computed tomography findings in unilateral allergic fungal rhinosinusitis cases

Overall, postoperative polyp grades had a mean±SD of 1.0±1.2. Postoperative Lund-Mackay scores had a mean±SD of 3.7±4.8. In patients with contralateral development and/or ipsilateral recurrence of disease, polyp grades had a mean±SD of 2.38±0.52, and Lund-Mackay scores had a mean±SD of 7.4±1.5 (Lund-Mackay score was calculated for each side separately in the single case that had bilateral disease). One case with contralateral development of AFRS also had lamina papyracea erosion (25%).

### Recurrence in unilateral versus bilateral allergic fungal rhinosinusitis

Although the information from bilateral AFRS cases is beyond the focus of the current study, we have documented the recurrence rate in bilateral AFRS patients managed at our institution. Out of the 36 bilateral cases operated, recurrence was reported in 22 (61.1%) patients. When comparing unilateral and bilateral AFRS, the recurrence rate in unilateral cases was significantly lower (18.8 vs. 61.1%;  $P=0.007$ ). However, because of the contralateral development of disease in 31.3% of the unilateral AFRS cases, the final need for another surgical intervention did not significantly differ between unilateral and bilateral AFRS cases (43.8 vs. 61.1%, respectively;  $P=0.24$ ).

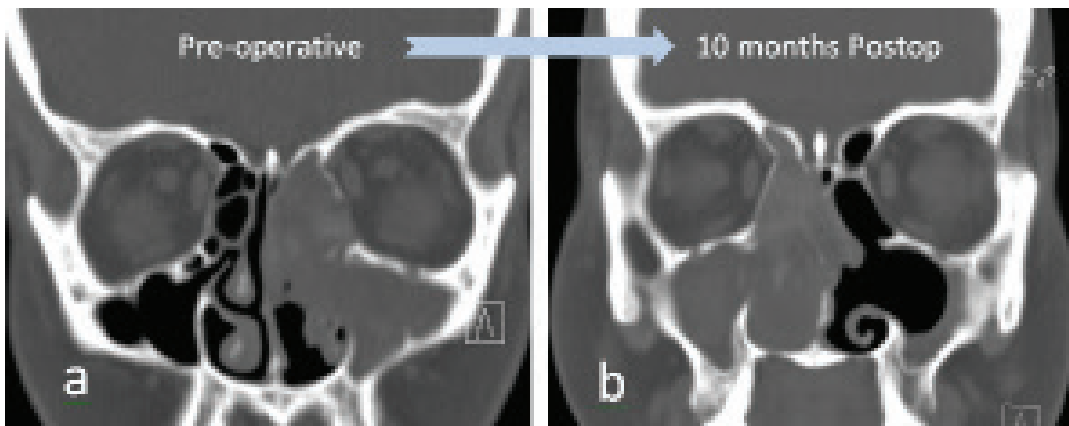
**Table 1 Prevalence and outcome of allergic fungal rhinosinusitis (AFRS) among 136 CRS patients treated with endoscopic sinus surgery (ESS) at our institution**

<b>136 CRS with or without nasal polyps treated with ESS</b>	<b>Not AFRS:</b> 84 (60.8%)		
	<b>Bilateral:</b> 36 (69.2%)	Post-operative Follow up	<b>Free:</b> 14 (38.9%)
	<b>Unilateral:</b> 16 (30.8%)		<b>Diseased:</b> 22 (61.1%)
	<b>AFRS:</b> 52 (38.2%)		Free: 9 (56.2%)
		<b>Diseased:</b> 7 (43.8%)	<b>Contralateral AFRS*:</b> 4 (25%) <b>Ipsilateral Recurrence **:</b> 2 (12.5%) <b>Bilateral AFRS* / **: 1 (6.25%)</b>

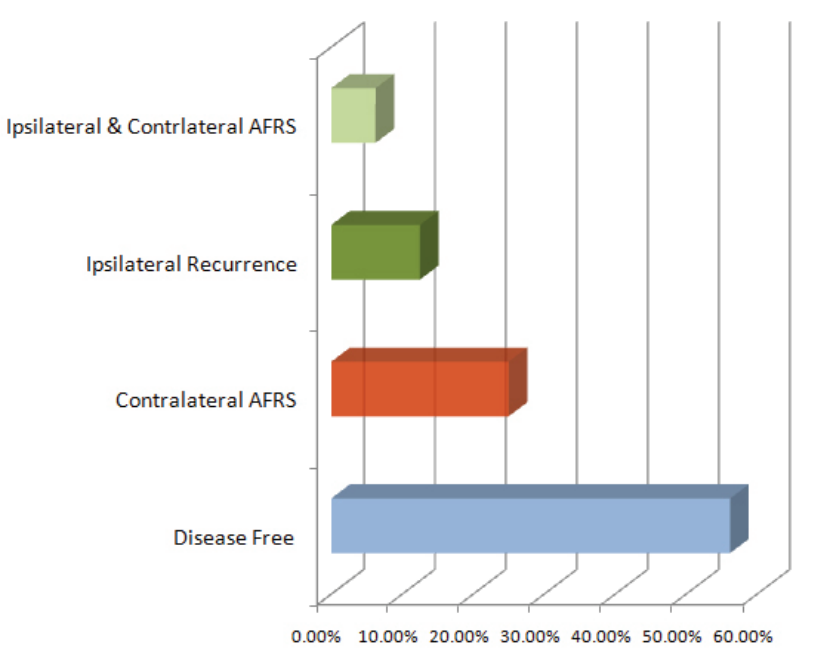
AFRS, allergic fungal rhinosinusitis; CRS, chronic rhinosinusitis; ESS, endoscopic sinus surgery

aTotal incidence of contralateral disease in unilateral AFRS equals: contralateral AFRS+bilateral AFRS – i.e. 25+6.25=31.3%

bTotal incidence of recurrence in unilateral AFRS equals: ipsilateral recurrence+bilateral AFRS – i.e. 12.5+6.25=18.8%



**Fig 1 (a) Preoperative computed tomography (CT) scan of left (unilateral) allergic fungal rhinosinusitis (AFRS) in a 22-year-old female patient (b) CT scan obtained 10 months postoperatively when development of contralateral AFRS was noted during routine postoperative follow-up**



**Fig 2 Outcome in 16 cases of unilateral allergic fungal rhinosinusitis (AFRS) cases during a mean postoperative duration of 24.8 months (range: 12–44 months)**

**Table 2 Reported prevalence of unilateral allergic fungal rhinosinusitis cases and their recurrence (Rec) rate (whenever described)**

Studies	Total no. AFRS cases	N (%) of unilateral cases	Recurrence rate
Current study	52	16 (30.8)	For unilateral AFRS: Contralateral AFRS: 31.3% Ipsilateral recurrence: 18.8% For bilateral AFRS: 61.1%
Zakirullah et al. [27]	23	16 (70)	18.75% for unilateral (vs. 85.7% of bilateral)
Al-Dousary [16]	59	20 (33.9)	Not studied
Thahim et al. [28]	20	12 (60)	Overall 20%
Zhou et al. [29]	21	10 (47.6)	Overall 33.3%
Gupta et al. [30]	132 (>15 years)	38 (28.8)	Overall 9.8%
Sohail et al [2]	32	20 (62.5)	22.7% for unilateral (vs. 30% for bilateral)
McClay [31]	100 (>17 years)	37	Not studied
Ferguson et al. [32]	192	96 (50)	Not studied
Mukherji et al. [15]	45	22 (49)	Not studied
Torres et al. [33]	16	7 (44)	Not studied

AFRS, allergic fungal rhinosinusitis.

aRecurrence was reported for both unilateral and bilateral cases altogether.

## Discussion

AFRS represents one of the distinctive forms of CRS with characteristic clinical and pathological presentation. The reported prevalence of AFRS among patients undergoing ESS is widely variable, and it is generally thought to be higher in warm and humid climates. In USA, it has been estimated that 5–10% of patients with CRS carry a diagnosis of AFRS. [22,23] A recent Iranian study found AFRS in 9.45% of patients with sinonasal polyposis [24]. Goh et al. [25] reported 26.7% prevalence of AFRS in adult Malaysian patients with refractory CRS. In India, Saravanan et al. [26] have studied 70 consecutive refractory CRS patients with or without nasal polyps and found AFRS in almost 50% of their studied sample. In another study in eastern Saudi Arabia, the prevalence of AFRS among patients with nasal polyposis was reported as 12.1% [20]. Our prevalence of AFRS was 38.2%, and this relatively higher percentage may be related to climate difference in our geographical area, or because of the fact that our hospital is a tertiary/quaternary care center with a tendency toward receiving more advanced and challenging cases, which is more frequent in AFRS.

Unilateral predominance of AFRS is frequently described in literature and has to be distinguished from strictly unilateral disease. For example, Bent and Kuhn reported 87% (13 out of 15) of their AFRS cases as unilaterally predominant. Mukherji et al. [15] also documented asymmetric involvement in 78% of bilateral cases. The reported prevalence of true unilateral disease varies widely from 28.8 to 70% of AFRS cases (Table 2), [2,15,16,27–33] and our 30.8% prevalence of unilateral AFRS lies within this range.

Since its description in the eighties of the last century, [3] various studies have discussed the clinical presentation and management of AFRS. However, many aspects of this disease entity still remain incompletely understood. The clinical behavior of unilateral AFRS cases is not an exception. The recurrence rate in unilateral AFRS has been seldom described. Zakirullah et al.[27] reported a recurrence rate of 18.5 versus 85.7% in unilateral and bilateral cases, respectively. However, Sohail et al. [2] found no statistically significant difference among both entities (22.5 vs. 30%), which might be because of their small sample size (Table 2).

In our study, the recurrence rate in unilateral AFRS cases was significantly lower than bilateral disease (18.8 vs. 61.1%), which may be explained by the theoretical less disease severity in cases with unilateral involvement. However, development of AFRS in the contralateral side affected the clinical outcome so that the need for another surgery was not statistically significant from bilateral cases.

To the best of our knowledge, none of the studies in literature has exclusively addressed postoperative behavior in unilateral AFRS cases. In the current study, the clinical outcome of unilateral AFRS patients managed at our institution over the preceding 3 years was investigated. In addition to ipsilateral recurrence in 12.5% of cases, another 25% have developed contralateral AFRS within 29 months after ESS (mean: 15 months). Furthermore, 1 (6.25%) patient presented with both ipsilateral recurrence and contralateral AFRS.

The reason for this contralateral development of AFRS is not clear, but it may be part of the natural disease process. We postulate that unilateral AFRS is an early stage in disease presentation that can eventually progress to bilateral disease. Contralateral development of AFRS may also be theoretically explained as the transfer of fungal antigens from the affected side to the healthy side because of intraoperative or postoperative irrigations. Nevertheless, this phenomenon should alert the surgeon that future development of contralateral AFRS needs to be part of patients' preoperative counseling. In addition, postoperative follow-up should be directed to both sinonasal passages.

A challenging question arises whether providing a prophylactic treatment to the contralateral side may have a role in certain cases such as aggressive disease or questionable follow-up. Clearly, current study findings do not justify operating normal uninvolved sides. The need for postoperative nasal sprays or local irrigation for both sides of the nose can be argued, and further investigation is needed. Whether treatment of the uninvolved side can be valuable in preventing future development of AFRS remains a question that definitely requires further research.

**Conclusion**

Postoperative development of contralateral AFRS is not infrequent and needs to be part of patients' counseling. Follow-up should be directed to both sinonasal passages to detect early development of contralateral disease or recurrence. The effect of current study findings on unilateral AFRS treatment plan requires further prospective studies, preferably with multicenter collaboration.

**Acknowledgements**

The authors would like to thank the Deanship of Scientific Research at Umm Al-Qura University for the continuous support. We also thank Dr. Abdullah Aburiziza, MBChB, ABP, FAAP, Assistant Professor and HOD, Pediatric Department, Umm Al-Qura University; and Dr. Abdullah Marghalani, BDS, MSD, DrP, Assistant professor, King Saud bin Abdulaziz University for Health Sciences, for their assistance during the course of this study.

**Financial support and sponsorship**

This work was supported by the Deanship of Scientific Research at Umm Al-Qura University to Dr. Osama Marghalani, (Grant Code: 15-MED-3-1-0033).

**References**

1. Matsuwaki Y, Ookushi T, Asaka D, Mori E, Nakajima T, Yoshida T, et al. Chronic rhinosinusitis: risk factors for the recurrence of chronic rhinosinusitis based on 5-year follow-up after endoscopic sinus surgery. *Int Arch Allergy Immunol.* 2008;146:77–81.
2. Sohail MA, Al Khabori MJ, Hyder J, Verma A. Allergic fungal sinusitis: can we predict the recurrence? *Otolaryngol Head Neck Surg.* 2004;131:704–710.
3. Laury AM, Wise SK. Allergic fungal rhinosinusitis. *Am J Rhinol Allergy.* 2013;27:S26–S27.
4. Marghani O. Update in the management of allergic fungal sinusitis. *Saudi Med J.* 2014;35:791–795.
5. Katzenstein AL, Sale SR, Greenberger PA. Allergic Aspergillus sinusitis: a newly recognized form of sinusitis. *J Allergy Clin Immunol* 1983;72:89–93.
6. Safirstein BH. Allergic bronchopulmonary aspergillosis with obstruction of the upper respiratory tract. *Chest.* 1976;70:788–790.
7. Miller JW, Johnston A, Lamb D. Allergic aspergillosis of the maxillary sinus. *Thorax.* 1981;36:710.
8. Fokkens WJ, Lund VJ, Mullol J, Bachert C, Alobid I, Baroody F, et al. EPOS 2012: European position paper on rhinosinusitis and nasal polyps 2012. A summary for otorhinolaryngologists. *Rhinology.* 2012;50:1–12.
9. Chakrabarti A, Denning DW, Ferguson BJ, Ponikau J, Buzina W, Kita H, et al. Fungal rhinosinusitis: a categorization and definitional schema addressing current controversies. *Laryngoscope.* 2009;119:1809–1818.
10. Han JK. Subclassification of chronic rhinosinusitis. *Laryngoscope.* 2013;123:S15–S27.
11. Guo C, Ghadersohi S, Kephart GM, Laine RA, Sherris DA, Kita H, Ponikau JU. Improving the detection of fungi in eosinophilic mucin: seeing what we could not see before. *Otolaryngol Head Neck Surg* 2012;147:943–949.
12. Gan EC, Thamboo A, Rudmik L, Hwang PH, Ferguson BJ, Javer AR. Medical management of allergic fungal

- rhinosinusitis following endoscopic sinus surgery: an evidence-based review and recommendations. *Int Forum Allergy Rhinol.* 2014;4:702–715.
13. Jang DW, Lachanas VA, Segel J, Kountakis SE. Budesonide nasal irrigations in the postoperative management of chronic rhinosinusitis. *Int Forum Allergy Rhinol.* 2013;3:708–711.
14. Bent JP III, Kuhn FA. Diagnosis of allergic fungal sinusitis. *Otolaryngol Head Neck Surg.* 1994;111:580–588.
15. Mukherji SK, Figueroa RE, Ginsberg LE, Zeifer BA, Marple BF, Alley JG, et al. Allergic fungal sinusitis: CT findings. *Radiology.* 1998;207:417–422.
16. Al-Dousary SH. Allergic fungal sinusitis: radiological and microbiological features of 59 cases. *Ann Saudi Med.* 2008;28:17–21.
17. Ryan MW. Allergic fungal rhinosinusitis. *Otolaryngol Clin North Am.* 2011;44:697–710.
18. Marple BF. Allergic fungal rhinosinusitis: current theories and management strategies. *Laryngoscope.* 2001;111:1006–1019.
19. Schubert MS. Allergic fungal sinusitis: pathophysiology, diagnosis and management. *Med Mycol.* 2009;47:S324–S330.
20. Telmesani LM. Prevalence of allergic fungal sinusitis among patients with nasal polyps. *Ann Saudi Med.* 2009;29:212–214.
21. Meltzer EO, Hamilos DL, Hadley JA, Lanza DC, Marple BF, Nicklas RA, et al. Rhinosinusitis Initiative Rhinosinusitis: developing guidance for clinical trials. *Otolaryngol Head Neck Surg.* 2006;135:S31–S80.
22. Thrasher RD, Kingdom TT. Fungal infections of the head and neck: an update. *Otolaryngol Clin North Am.* 2003;36:577–594.
23. Schubert MS. Allergic fungal sinusitis. *Otolaryngol Clin North Am.* 2004;37:301–326.
24. Bakhshae M, Fereidouni M, Mohajer MN, Majidi MR, Azad FJ, Moghiman T. The prevalence of allergic fungal rhinosinusitis in sinonasal polyposis. *Eur Arch Otorhinolaryngol.* 2013;270:3095–3098.
25. Goh BS, Gendeh BS, Rose IM, Pit S, Samad SA. Prevalence of allergic fungal sinusitis in refractory chronic rhinosinusitis in adult Malaysians. *Otolaryngol Head Neck Surg* 2005; 133:27–31.
26. Saravanan K, Panda NK, Chakrabarti A, Das A, Bapuraj RJ. Allergic fungal rhinosinusitis: an attempt to resolve the diagnostic dilemma. *Arch Otolaryngol Head Neck Surg* 2006; 132:173–178.
27. Zakirullah, Nawaz G, Sattar SF. Presentation and diagnosis of allergic fungal sinusitis. *J Ayub Med Coll Abbottabad.* 2010; 22:53–57.
28. Thahim K, Jawaid MA, Marfani MS. Presentation and management of allergic fungal sinusitis. *J Coll Physicians Surg Pak* 2007; 17:23–27.
29. Zhou B, Liu M, Han DM, Wang ZC, Zhang L, Xian JF, et al. Characteristics of computed tomography of allergic fungal sinusitis. *Zhonghua Er Bi Yan Hou Tou Jing Wai*

Ke Za Zhi 2006; 41:493–496.

30. Gupta AK, Bansal S, Gupta A, Mathur N. Is fungal infestation of paranasal sinuses more aggressive in pediatric population? *Int J Pediatr Otorhinolaryngol* 2006;70:603–608.
31. McClay JE, Marple B, Kapadia L, Biavati MJ, Nussenbaum B, Newcomer M, et al. Clinical presentation of allergic fungal sinusitis in children. *Laryngoscope*

2002;112:565–569.

32. Ferguson BJ. Eosinophilic mucin rhinosinusitis: a distinct clinicopathological entity. *Laryngoscope*. 2000;110:799–813.
33. Torres C, Ro JY, El-Naggar AK, Sim SJ, Weber RS, Ayala AG. Allergic fungal sinusitis: a clinicopathologic study of 16 cases. *Hum Pathol*. 1996;27:793–799.