

Role of open reduction and semirigid internal fixation in management of displaced pediatric mandibular fractures

Mohamed El Sayed Hassan, Hossam Abd El Hay Gad,
Wael H.G. Abd Elkawy

Department of Otorhinolaryngology, Faculty of Medicine, Benha University, Benha, Egypt

Correspondence to Wael H.G. Abd Elkawy, M.B.B.Ch, M.Sc. Otolaryngology Military Medical Academy, Cairo, Egypt.
Tel: +201012364844
e-mail: waelgad09@gmail.com

Received 31 December 2020

Revised 21 February 2021

Accepted 23 February 2021

Published 31 March 2022

Pan Arab Journal of Rhinology

2021, 11:83–88

Background

Injuries in children are very common, and nine million children from birth to the age of 19 years are treated every year in the emergency departments for accidental injuries, costing \$87 billion. Involuntary injury is ranked as the number one cause of illness and death in children 1 year and older. Facial fractures are relatively rare in children and account for 1–15% of all facial fractures.

Aim

To evaluate the efficacy of open reduction and semirigid internal fixation in the management of displaced pediatric mandibular fractures.

Patients and methods

This study was conducted on 25 patients who have mandibular fracture. All cases were subjected to open reduction and semirigid internal fixation mandibular fractures. This study was carried out at the Otorhinolaryngology Department at Benha University Hospital and El Galaa Military Medical Complex in the period from May 2019 to May 2020.

Results

Fixation was done in all of the cases by 1.5-mm titanium miniplates and 1.5-mm diameter 7- or 9-mm length titanium screws, with plate removal after 6 months.

Conclusion

Open reduction and semirigid internal fixation with titanium miniplates is a reliable and a safe method in the treatment of displaced fractures of the pediatric mandible, with no danger regarding the erupted or unerupted tooth follicles.

Keywords:

displaced pediatric mandibular fractures, open reduction, semirigid internal fixation

Pan Arab J Rhinol 11:83–88

© 2022 2090-7640

Introduction

The diagnosis of facial fractures in the pediatric population can be difficult. These fractures can be overlooked by imaging and are frequently underreported. The conservative management of facial fractures in pediatric patients is often satisfactory, but at other times, it can be complicated and challenging, and the approach to facial fracture management is distinct in this patient population [1].

The occurrence of facial fractures in children is lower than in adults. Fractures in children are often more difficult to detect. In particular, facial fractures and mandibular fractures are sometimes subtly present, often with minimal pain or swelling. It can also be difficult to interact with a young child. Therefore, a thorough clinical examination of the facial skeleton is important to prevent missed fractures. This systematic review must be carried out on any patient in whom the mode of injury gives rise to suspicion of potential facial injury [2].

In children, the ratio of skull to face is 8 : 1. This ratio is 3 : 2 by early adolescence and 2 : 1 by adulthood. Relatively broader cranium and forehead effectively protect the lower and middle thirds of the face from injury. Frontal

and maxillary sinuses are not well formed in young children. These factors contribute to the unique fracture trends found in children and the incidence of skull and upper orbital rim fractures. As the infant grows and the facial skeleton and mandible become more prominent, injuries to these regions become more prevalent [3].

Over the last few decades, steady progress has been made in the treatment of craniomaxillofacial injuries in infants. New methods and materials for internal fixation have complemented conventional techniques. There has been less improvement in the treatment of mandible fractures during deciduous and mixed dentures. The treatment of the growing mandible continues to be the most contentious of all facial fractures. The goal of a child's repair of mandible fractures is to create a functional occlusion and to reduce any possible effect on normal development [4].

Treatment modalities of mandibular fractures differ depending on the skill, familiarity, concerns, and values

This is an open access article distributed under the terms of the Creative Commons Attribution-NonCommercial-ShareAlike 3.0 License, which allows others to remix, tweak, and build upon the work non-commercially, as long as the author is credited and the new creations are licensed under the identical terms.

of the operator. Treatment methods include observation with or without physiotherapy, cautious management with practical appliances, closed reduction strategies as well as open reduction and internal fixation [5].

The purpose of the internal fixation is the early mobilization of the affected portion. The technological and biological criteria for the selection of the treatment method are therefore total stability and primary bone healing. Both involve a departure from the conventional definition of bone surgery [6].

Open reduction and internal fixation removes the need for magnetomotive force (MMF), which directly improves airway control, preserves oral hygiene, and improves nutritional support [7].

Aim

The aim was to evaluate the efficacy of open reduction and semirigid internal fixation in the management of displaced pediatric mandibular fractures.

Patients and methods

This study was conducted on 25 patients who have mandibular fracture. All cases were subjected to open reduction and semirigid internal fixation mandibular fractures. This study was carried out at the Otorhinolaryngology Department at Benha University Hospital and El Galaa Military Medical Complex in the period from August 2019 to May 2020. The protocol was approved by IRB and ethical committee of Banha faculty of medicine 2018. All enrolled patients gave written informed consent.

The medical and surgical records were reviewed prospectively, and the patients were followed up for 1 year.

Inclusion criteria for the study population were as follows:

- (1) Mandibular pediatric fracture age of mixed dentation (6–13 years old).
- (2) Unfavorable displaced mandibular fracture.
- (3) Symphyseal and parasymphyseal fracture with marked displacement.
- (4) Debris and soft tissue interposed between fragments.
- (5) Medically compromised patients with mental and nutritional disturbances.
- (6) Insufficient number of teeth.

Exclusion criteria for the study population were as follows:

- (1) Unfit for surgery or general anesthesia.

- (2) Severe comminuted and compound fractures.
- (3) No soft tissue to cover fracture site.
- (4) Evidence of osteomyelitis.
- (5) Bacterial infection.

Preoperative tests

History

A comprehensive history of onset, length, exacerbations, complications, if established, and any prior maxillofacial surgery was taken with particular concern.

Preoperative evaluation

The wound was washed, and the fracture site was examined before surgery to verify the occlusion of the mouth and the vitality of the tooth. Any symptoms of inflammation (bacterial infection) have been removed.

Preoperative laboratory investigations

Comprehensive blood count, liver enzymes, urea, creatinine, blood sugar, bleeding time, clotting time, hepatitis viral markers, and chest radiograph were done.

Preoperative radiographic imaging

Orthopantomograph/facial computed tomography (CT) for the assessment of head injury and facial fracture was done, following assessment and fitness approval by the pediatrician and anesthesiologist.

Informed consent

Patients had been adequately informed of the procedure, and a written consent had been taken from a legal guardian in light of the general concept of surgery, postoperative treatment, and operational risks, including complications of general anesthesia (stroke and heart attack, etc.).

Surgical procedure

The infant was placed supine on the operating room table with the neck slightly extended and the head resting in a sniffing position on the horseshoe headrest. The oral cavity and teeth are thoroughly cleaned with chlorhexidine gluconate oral rinse, and a moistened throat pack is put in position. The surgical area is then made sterile by a well-trained staff to include the face, head, and neck, to account for intraoperative manipulation and repositioning of the head and then draping. Surgery was done under general anesthesia and nasal intubation.

After injection of gingivobuccal sulcus with epinephrine-containing local anesthetic 1/200 000, an

incision is made to maintain a submucosal and muscle cuff on the part of the incision close to the attached gingiva for ease of approximation during the closure of the mentalis muscle, which is to be tangentially cut to the lower boundary. The mandible is commonly exposed in the subperiosteal plane to promote instrumentation. Care is taken to avoid damage to the mental nerve when it emerges from the foramen; sometimes, for ease of retraction, the periosteal sheath covering the nerve may need to be carefully incised and the nerve dissected from the surrounding tissue.

Irrigation is applied after the fracture has been exposed. Any fibrin clot or fracture hematoma at the fracture site is thoroughly debrided to allow segment mobilization and manipulation.

Until reduction and fixation when multiple fractures are present, all fractures are extensively exposed to subperiosteal dissection.

After fracture exposure, the patient is put in the MMF with close examination of the facets of wear on the occluding teeth and of the mandible condyles within the glenoid fossae.

Fragments of fracture are reduced and flattened only after a pre-injury occlusion has been created. Bigonial pressure may need to be exerted if there is a large show of mandible angles. Reduction of broken segments may be difficult for a pediatric patient, as there may be contact with dental follicles.

Occasionally, the fracture may have a greenstick portion on the opposite (lingual) cortex, which may interfere with an effective reduction. Owing to the substantial predicted postoperative bone remodeling and rapid healing in infants, a minor bone gap at the fracture site can be tolerated if the pre-injury occlusion is restored and is typically of no significance. The miniplate fixation should be used after the pre-injury occlusion has been identified in MMF.

Care should be taken as drill holes are positioned to prevent further damage of the tooth buds. The lateral bony cortex covering the tooth bud is ~1-mm thick and the screws can easily damage the underlying developing tooth follicles, hence miniplates are positioned at the lower edge of the mandible to prevent injury to the tooth follicles.

If required, a longer plate may be used to prevent drilling holes in dental areas. For all forms of fractures, regardless of position, a minimum of two screws should be positioned on either side of the fracture for stable fixation. After open reduction and internal fixation has been applied, the MMF is published. The arch bars act

as an additional fixing point, similar to the resistance band of the mandible, and allow for the postoperative positioning of the elastics when malocclusion or open bites are present. In the case of mixed dentation, arch bars may be accommodated.

The bridle wire that connects the teeth along the fracture line may also function as a tension band.

Intraoral incisions are closed with a mixture of running or interrupted Vicryl suture, with care to clear the mucosa from the incisions. For the symphyseal and parasymphyseal areas, the mentalis muscle should be resuspended with a buried muscular suture (three stitches one at the median raphe and two stitches on each belly) to avoid secondary chin ptosis and 'witch chin' deformity.

The neck pack is removed and the oropharynx is suctioned with a nasogastric hose. The patient is normally extubated at the conclusion of the surgery.

The patient received intravenous antibiotics for 24 h in the hospital. The patient was followed up as follows:

Follow-up after 2 h from surgery:

- (1) Monitoring of oral intake.
- (2) Check airway.
- (3) Check vital data of patient.
- (4) Inspection of edema or hemorrhage.

Follow-up after 1 week:

- (1) Check for normal occlusion.
- (2) Wound healing.
- (3) Removal of the stitches.
- (4) Panorama for the wound.
- (5) Tooth vitality.

Follow-up after 3 and 6 months:

CT and panorama were done, and mouth and tooth occlusions were checked. Removal of plate and screws was done at 6 months.

Results

Fixation was done in all of the cases by 1.5-mm titanium miniplates and 1.5-mm diameter 7- or 9-mm length titanium screws, with plate removal after 6 months.

Table 1 shows that 16 (64%) were male and nine (36%) were female.

Table 2 shows that the most common cause of mandibular fractures in our series was motor accidents, representing 72% (18 patients) of all cases. One (4%)

patient of these cases was recognized as secondary to child abuse.

Biking accidents occurred in one (4%) case.
 Falls from high occurred in three (12%) cases.
 Sporting injuries occurred in one (4%) case.
 Animal kick occurred in one (4%) case.

The association between mandibular fractures and airway compromise is very low in our series. Only two patients required airway control for obstruction. In these cases, intubation was indicated for soft-tissue edema secondary to a neck injury. All intubations were performed in the emergency department by an anesthesiologist using direct laryngoscopy and oral intubation. Tracheostomy or fiberoptic intubation was not necessary.

Broken or loosened teeth were noted in eight patients. There were no cases of broken or lost teeth that were aspirated (Tables 3 and 4).

The anatomic location of fractures varied:

- (1) Parasymphiseal occurred in nine of the cases.
- (2) Symphyseal area (nine cases).
- (3) Angle (four cases).
- (4) Bilateral angle (three cases).
- (5) No ramus or coronoid process fractures were seen.

Table 1 Demographic data of the patients

	<i>n</i> (%)
Age of patients (years)	
6-8	6 (24)
9-10	7 (28)
11-12	12 (48)
Sex of patient	
Male	16 (64)
Female	9 (36)

Table 2 Causes of mandibular fractures

Cause of mandibular fractures	<i>n</i> (%)
Motor accidents	18 (72)
Child abuse	1 (4)
Biking	1 (4)
Fall from high	3 (12)
Animal kick	1 (4)
Sporting	1 (4)
Total	25 (100)

Table 3 The anatomic location of fractures

Location of fractures	<i>n</i> (%)
Parasymphiseal	9 (36)
Symphiseal	9 (36)
Angle	4 (16)
Bilateral angle	3 (12)
Total	25 (100)

Number of fractures

Clinically primary wound healing was achieved. Postsurgical infections were seen in two cases that were successfully managed with localized intraoral incision and drainage and oral antibiotic therapy in the clinic under local anesthesia.

All patients also had either erupted or partially bony impacted teeth, which interfered with reduction removed at the time of surgery, with sliding buccal flap closures.

All children had good alignment and proper occlusion without any discrepancy postoperatively.

All cases showed initial stability of fracture segments bimanually intraoperatively, which increased all over follow-up periods after 1 week, 1, and 3 months.

Regarding radiographic results, the second postoperative day panoramic radiograph showed accurate reduction and excellent vertical alignment of the fracture segments in all cases.

Radiographic examination after 1 month postoperatively revealed no change in the position of the fractured segments or plates, and the fracture line was still easily detected until the first month postoperatively.

After 3 months, the radiographic examination revealed that the fracture line could be hardly detected.

There were no complaints of dental problems adjacent to the screws. Teeth vitality tests by CT and panorama were done and indicated that no dental damage occurred in any patient.

Other complications including screw loosening (five screws in three patients) and bone coverage over screws (eight sites in four patients) were observed.

Temporo-mandibular disorders (TMDs) were recorded, including joint pain (in three patients) and clicking of the fracture/nonfracture side (in one patient). There was no limitation of mouth opening (Table 5).

Discussion

The aim of this study was to evaluate the efficacy of open reduction and semirigid internal fixation in the management of displaced pediatric mandibular fractures and possible complications (Fig. 1 and 2).

Mandibular fracture is one of the major causes of morbidity in infants. Mandibular fractures in young ages

Table 4 Pattern of fractures

Pattern of fracture	n (%)
Single fracture	22 (88)
Multiple fractures	3 (12)

Table 5 Postoperative complications

Complication	Number of complicated cases	Total number of cases [n (%)]
Wound infection	2	25 (8)
Wound dehiscence	1	25 (4)
Paresthesia	1	25 (4)
Malocclusion, delayed, and malunion	0	25 (0)
Primary hemorrhage	0	25 (0)
Plate fracture	0	25 (0)
Screw loosening	0	25 (0)

can lead to impaired functioning and disfigurement. Patterns and etiologies of mandibular fractures differ by geographical location, cultural characteristics, and socioeconomic status. Most studies have shown that males are more vulnerable to maxillofacial trauma than females in all age groups. The male–female ratio of maxillofacial trauma and mandibular fractures is usually 2 : 1. The findings of our research showed substantial sex bias between males and females (64 : 36). In comparison, Cole *et al.* [8] showed that there was no significant sex bias.

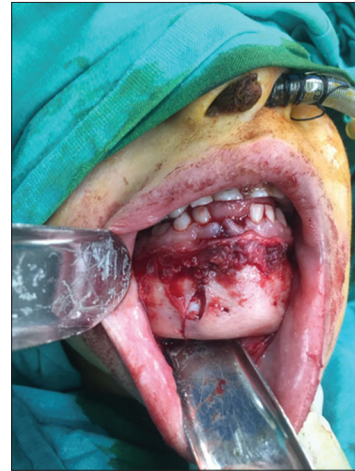In this analysis, only 24% of the fractures were recorded among those less than the age of 9 years, but the key age was 9 years (9 : 12). This may be owing to the fact that younger age groups face more parental control and less freedom than older children. Participation in school activities and increased social contact can increase the risk of maxillofacial trauma in this age group.

Motor accidents were the key cause of mandibular fracture in this report (72%). Our results are in contrast with the observations of Collao-González *et al.* [9], Joshi *et al.* [10], Namdev *et al.* [11], Owusu *et al.* [12], Kumaraswamy *et al.* [13], and Atilgan *et al.* [14].

Kumaraswamy *et al.* [13] found that in children up to 6 years of age, falls in the home were the most common mode of maxillofacial trauma, and with a rise in age and more outdoor exposure, falls continued to occur outside the home (Fig. 3).

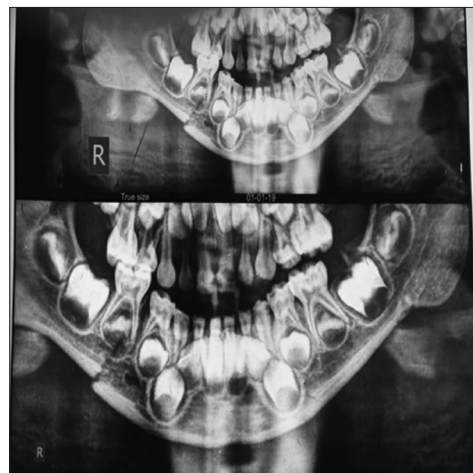
This research found that athletics and cycling is the second most common cause of mandibular fracture. In this study, play-related or sports-related injuries increased with age, and the highest incidence was found in the 10- to 12-year age range. Muraoka *et al.* [15] have also documented similar trends among Japanese children. Increased occurrence of fractures during puberty and adolescence may be owing to

Figure 1



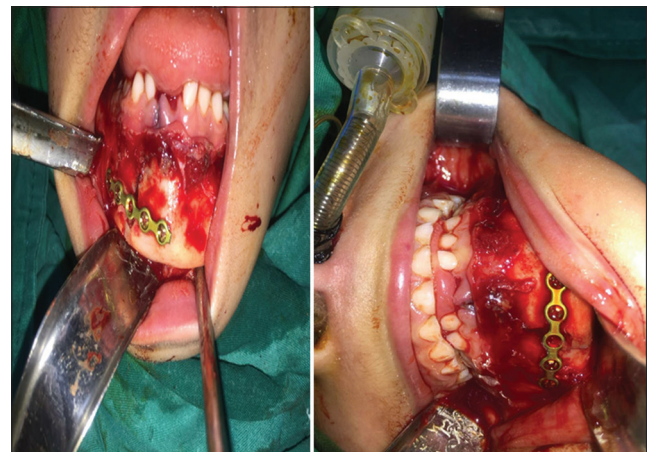
Fracture line before fixation.

Figure 2



Preoperative panorama of the fracture.

Figure 3



Splint fixation of the fracture.

increased participation in sports. Schlievert[16] and Knoche *et al.* [17] stated that child neglect was one cause of mandibular fracture in infants. In this study,

one case of child neglect, similar to the trend observed by Almahdi and Higzi [18], Gassner *et al.* [19], Atilgan *et al.* [14], and Tanaka *et al.* [20], was found to be a significant etiology for pediatric facial fractures. In contrast, Namdev *et al.* [11] and Fasola *et al.* [21] did not recognize child neglect as a mandibular fracture mechanism.

The symphyseal and parasymphyseal regions were the most common mandibular fracture sites in this study (72%). Our findings are in contrast with other studies, such as Joshi *et al.* [10], Namdev *et al.* [11], Owusu *et al.* [12], and Shi *et al.* [22], which reported condylar fractures as more common.

In this study, wound infection is the most common complication that occurred after repair (8%), followed by wound dehiscence (4%) and paresthesia (4%). No cases of malocclusion or malunion were found after 1 year of follow-up, as opposed to Joshi and colleagues where two cases of malunion were found.

Conclusion

Open reduction and semirigid internal fixation with titanium miniplates is a reliable and safe method in the treatment of displaced fractures of the pediatric mandible.

Financial support and sponsorship

Nil.

Conflicts of interest

There are no conflicts of interest.

References

- 1 Lim CA, Singh YK, Portnof JE, Blumberg SM. Pediatric maxillofacial trauma: a review of 156 patients. *J Oral Maxillofac Surg* 2016; 74:1420.
- 2 Bholra N, Jadhav A, Borle R, Khemka G, Adwani N, Bhattad M. Lateral compression open cap splint with circummandibular wiring for management of pediatric mandibular fractures: a retrospective audit of 10 cases. *Oral Maxillofac Surg* 2014; 18:65–68.
- 3 Haug RH and Foss J. Maxillofacial injuries in the pediatric patient. *Oral Surg Oral Med Oral Pathol Oral Radiol Endodontol* 2000; 90:126–134.
- 4 Sheikh Z, Najeeb S, Khurshid Z, Verma V, Rashid H and Glogauer M. Biodegradable materials for bone repair and tissue engineering applications. *Materials* 2015; 8:5744–5794.
- 5 Zimmermann CE, Troulis MJ and Kaban LB. Pediatric facial fractures: recent advances in prevention, diagnosis and management. *Int J Oral Maxillofac Surg* 2005; 34:823–833.
- 6 Peterson LJ. 2012. Peterson's principles of oral and maxillofacial surgery (Vol. 1). PMPH-USA 2006;62:89.
- 7 Pasha R and Golub JS. Otolaryngology-head and neck surgery: clinical reference guide. San Diego, USA: Plural Publishing; 2017.
- 8 Cole P, Kaufman Y, Hollier LH Jr Managing the pediatric facial fracture. *Cranio-maxillofac Trauma Reconstr* 2009; 2:77–83.
- 9 Collao-González C, Carrasco-Labra A, Sung-Hsieh HH, Cortés-Araya J. Epidemiology of pediatric facial trauma in Chile: a retrospective study of 7,617 cases in 3 years. *Med Oral Patol Oral Cir Bucal* 2014; 19:e99–e105.
- 10 Joshi SR, Saluja H, Pendyala GS, Chaudhari S, Mahindra U, Kini Y. Pattern and prevalence of maxillofacial fractures in rural children of central Maharashtra, India. A retrospective study. *J Maxillofac Oral Surg* 2013; 12:307–311.
- 11 Namdev R, Jindal A, Bhargava S, Dutta S, Singhal P, Grewal P. Patterns of mandible fracture in children under 12 years in a district trauma center in India. *Dent Traumatol* 2016; 32:32–36.
- 12 Owusu JA, Bellile E, Moyer JS, Sidman JD. Patterns of pediatric mandible fractures in the United States. *JAMA Facial Plast Surg* 2016; 18:37–41.
- 13 Kumaraswamy SV, Madan N, Keerthi R, Singh DS. Pediatric injuries in maxillofacial trauma: a 5 year study. *J Maxillofac Oral Surg* 2009; 8:150–153.
- 14 Atilgan S, Erol B, Yaman F, Yilmaz N, Ucan MC. Mandibular fractures: a comparative analysis between young and adult patients in the southeast region of Turkey. *J Appl Oral Sci* 2010; 18:17–22.
- 15 Muraoka M, Nakai Y, Nakagawa K, Yoshioka N, Nakaki Y, Yabe T, *et al.* Fifteen-year statistics and observation of facial bone fracture. *Osaka City Med J* 1995; 41:49–61.
- 16 Schlievert R. Infant mandibular fractures: are you considering child abuse? *Pediatr Emerg Care* 2006; 22:181–183.
- 17 Knoche JW, LeBlanc KK, King TW, Knox BL. An infant with a unilateral mandibular fracture: when to consider nonaccidental trauma. *Clin Pediatr (Phila)* 2012; 51:404–407.
- 18 Almahdi HM, Higzi MA. Maxillofacial fractures among Sudanese children at Khartoum Dental Teaching Hospital. *BMC Res Notes* 2016; 9:120.
- 19 Gassner R, Tuli T, Hächl O, Rudisch A, Ulmer H. Cranio-maxillofacial trauma: a 10 year review of 9,543 cases with 21,067 injuries. *J Craniomaxillofac Surg* 2003; 31:51–61.
- 20 Tanaka N, Uchida N, Suzuki K, Tashiro T, Tomitsuka K, Kimijima Y, *et al.* Maxillofacial fractures in children. *J Craniomaxillofac Surg* 1993; 21:289–293.
- 21 Fasola AO, Obiechina AE, Arotiba JT. Fractures of the mandible in children. *East Afr Med J* 2001; 78:616–618.
- 22 Shi J, Chen Z, Xu B. Causes and treatment of mandibular and condylar fractures in children and adolescents: a review of 104 cases. *JAMA Otolaryngol Head Neck Surg* 2014; 140:203–207.