

Electron microscope of the nasal septal body versus the inferior turbinate

Yasser M. H. Mandour^a, Ahammed Allam^a, Hossam A. Gad^a, Eslam Farid^a, Nesrine Ebrahim^b, Samr Badie^a

Departments of ^aOtorhinolaryngology and ^bHistology, Faculty of Medicine, Benha University, Benha, Egypt

Correspondence to Dr. Yasser M. H. Mandour, MD, Department of Otorhinolaryngology, Faculty of Medicine, Benha University, Benha, Egypt
Tel: +20 100 970 4937; zip code:331030
e-mail: ghader_massoud@yahoo.com

Received 16 November 2021

Revised 22 January 2022

Accepted 28 January 2022

Published 31 March 2022

Pan Arab Journal of Rhinology

2021, 11:151–156

Background

The nasal septal body is located superior to the inferior turbinate and consists of septal cartilage thicker than the rest of septal mucosa.

Object

To clear the ultrastructural relation between nasal septal body and inferior turbinate using electron microscope.

Patients and methods

Biopsies of the nasal septal body and inferior turbinate were stained with hematoxylin–eosin and with Masson's trichrome stain and Periodic acid–Schiff (PAS) stain. Photomicrography with morphometric analysis was used to determine the relative area proportions of each tissue type.

Results

Nasal septal body has a prominence of glandular tissues with a mean proportion of 19.89%, in contrast to inferior turbinate, which had 7.89%. Inferior turbinate was found to have a prominence of collagen fibers with a mean proportion of 26.58%, in contrast to the septal body, which had 13.76%. By electron microscope, epithelium of the septal body had a large number of cilia and microvilli, the junctional complex between the cells were the tightly sealed zone (tight junction), while inferior turbinate mucosa had less number of cilia than that of septal body epithelial cells.

Conclusion

The presence of venous sinusoids and abundant seromucinous glands in the nasal septal swell body and its histological and ultrastructural similarity to inferior turbinate should guide to surgically reduce nasal septal body volume.

Keywords:

inferior turbinate, nasal septal body, nasal septum, erectile tissue

Pan Arab J Rhinol 11:151–156

© 2022 2090-7640

Introduction

The nasal septal body (also known as the septal turbinate, septal cavernous body, or septal erectile tissue) is a dilated portion of the anterior nasal septum located roughly 0.7–1.5 cm above the nasal floor, superior to the inferior turbinate and before the middle turbinate [1,2]. Anterior rhinoscopy, nasal endoscopy, and sinonasal imaging tests can all detect this mucosal-lined edema [1,3].

Septal cartilage makes up the septal body, which is typically a few millimeters thicker than the remainder of the septum.

The mucosa that covers the septal body is also thicker than the mucosa that covers the rest of the septum [4]. MRI scans revealed indications of congestive changes in the mucosa of the nasal septal body during the nasal cycle [5]. Surgically reducing the nasal septal body volume, as well as the inferior turbinates, decreased nasal obstruction and resulted in a considerable increase in nasal cross-sectional area and volume, with minimal side effects [6].

On the histological and morphometric differences of the mucosal lining and ultrastructure of the nasal septal body, rhinologists are divided.

Additional research is needed to have a better knowledge of the septal body (particularly the vascular and glandular systems), and its role may be clinically significant [1,7].

Patients and methods

The study was conducted between March 2019 and December 2019 on 20 patients (11 males/nine females) attending the ENT outpatient clinic of Benha University Hospitals and suffering from deviated nasal septum with or without hypertrophied inferior turbinate aged 18–49 years (mean, 33.5 years) and

This is an open access journal, and articles are distributed under the terms of the Creative Commons Attribution-NonCommercial-ShareAlike 4.0 License, which allows others to remix, tweak, and build upon the work non-commercially, as long as appropriate credit is given and the new creations are licensed under the identical terms.

having none of the exclusion criteria. The local ethics committee approval and informed consent had been obtained before the onset of this study.

Preoperative preparation

All patients were evaluated with a complete medical history, a nasal examination using a nasal speculum with suitable lighting and rigid nasal endoscopy, and full preoperative investigations.

A computed tomography scan of the nose and paranasal sinuses was also performed to assess the paranasal sinuses and establish the thickness and position of the nasal septal body in both coronal and axial sections (Fig. 1).

Exclusion criteria:

- (1) Previous history of nasal surgery.
- (2) Nasal polyposis.
- (3) Acute sinusitis.
- (4) Systemic illness like uncontrolled diabetes and hypertension.
- (5) History of topical nasal spray treatment in the past month.
- (6) History of drug abuse or exposure to irritants.

Intraoperative

Unilateral biopsies of the nasal septal body (from the side with compensatory hypertrophy) and the adjacent inferior turbinate were collected under general anesthesia during standard septoplasty with or without partial inferior turbinectomy. A mucosal incision on the anterior aspect of the septal body was made with a blade after a submucosal injection of a local anesthetic solution comprising 2% lidocaine and 1:100 000 epinephrine. Submucoperichondrial dissection would be performed through a mucosal incision, and a submucosal pocket was created, and biopsy from the

septal body (tissues were cut into small pieces of about 1 mm in diameter) was taken with great care to avoid damaging the surface mucosa, as well as biopsy from the adjacent inferior turbinate. Biopsies taken would be washed with normal saline before being placed in the fixative and sent for processing. The mucosal incision was left open, and silastic stents were sutured and put on both sides of the nasal septum with nasal packing.

- (1) Preparation for hematoxylin–eosin, Masson's trichrome, and PAS stain: specimens were routinely stained with hematoxylin–eosin after embedding in paraffin and serial sectioning at 5- μ m intervals; representative sections were separately stained with Masson's trichrome stain to allow better differentiation of stromal elements (blue-green) from the smooth muscle (red) of vascular structures, as well as stained with to allow better recognition of glandular tissue.

Both staining methods effectively visualized epithelial features and seromucinous glands.

Morphometric study: using the Image-Pro Plus program, version 6.0, the mean area percent of collagen fiber deposition and PAS positive reaction was assessed in five images from five nonoverlapping fields of each patient (Media Cybernetics Inc., Bethesda, Maryland, USA).

- (2) Preparation of ultrathin sections for transmission electron microscopy:

The blocks were trimmed and areas for further electron microscopic investigation were identified.

Ultrathin sections were cut, collected on copper grids, and stained with 4% uranyl acetate and lead nitrate. Sections were examined and electron micrographs were taken using a transmission electron microscope JOEL (JEM-100 SX, Akishima, Tokyo, Japan) in Tanta University's Electron Microscope Unit.

Postoperative

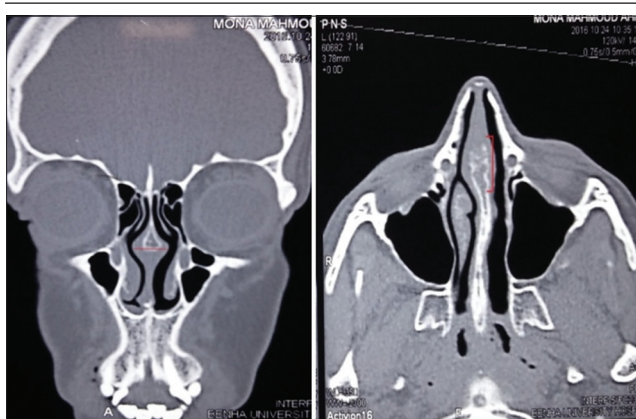
The nasal packs were removed the day following surgery, and patients were discharged from the hospital to be seen again in 10 days for the removal of nasal splints, and then in 2 weeks and 1 month for follow-up of the degree of improvement in nasal obstruction.

Statistical analysis

For quantitative data, mean and SD would be used; for qualitative data, frequency and distribution would be used.

The paired *t* test and Wilcoxon test would be used to compare quantitative data (*Z* test).

Figure 1



Computed tomography image coronal view (right) and axial view (left) of nasal septal body.

All data would be tabulated and analyzed with the SPSS (Statistical Package for the Social Sciences, IBM/SPSS Inc., Chicago, IL), version 20 computer application.

In all analyses, a *P* value of 0.05 would be deemed statistically significant, whereas a *P* value of 0.01 would be regarded highly significant.

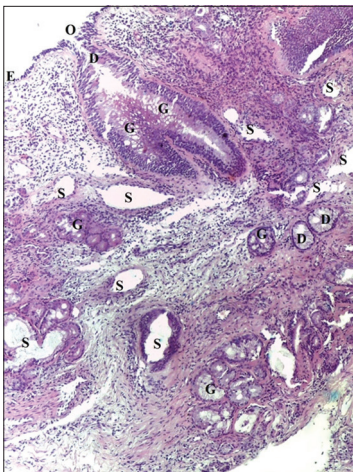
Results

The nasal septal body is covered by pseudostratified columnar ciliated epithelium with goblet cells. The epithelium of the septal body shows tall columnar cells and some invaginations mostly to increase the surface area with thickened basement membranes, and the inferior turbinate is covered by a pseudostratified columnar ciliated epithelium with goblet cells, less crowded and thinner than the septal body. No invaginations are seen with a thinner basement membrane. Seromucinous glands and venous sinusoids are abundant in the submucosa of the nasal septal body.

Branching seromucinous glands are visible (Fig. 2), indicating that these glands have strong secretory activities, but they are less abundant in the inferior turbinate and venous sinusoids, which are less in number and size than the septal body.

The inferior turbinate submucosa has been found to have a more developed fibrous stroma than the septal body.

Figure 2



Photomicrograph of the nasal septal body mucosa and submucosa showing the epithelium (E) is of pseudostratified columnar ciliated epithelium type with goblet cells, and the submucosa shows numerous seromucinous glands (G), ducts (D), some are branching opening on the surface by their opening (O) and venous sinusoids (S) (hematoxylin–eosin, ×100).

Sections stained with Masson's trichrome and Periodic acid–Schiff

The stained sections show that the inferior turbinate has a prominence of collagen fibers with a mean proportion of 26.58% in contrast to the septal body, which had 13.76%. Septal swell body was found to have a prominence of glandular tissues with a mean proportion of 19.89%, in contrast to the IT, which had 7.89% as illustrated by Tables 1 and 2 and Histograms 1 and 2.

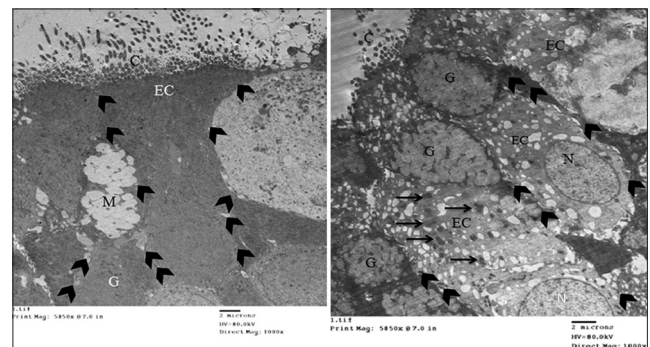
At ultrastructural level by transmission electron microscope

Epithelial cells of the septal body have a large number of cilia and microvilli at their free border and with obviously noted intraepithelial goblet cells (full with mucus) and are closely opposed to its neighbors, the junctional complex between the cells are a tightly sealed zone (tight junction) with apical junctional complexes, while inferior turbinate mucosa shows less number of cilia implantation in the apical surface than that of septal body epithelial cells. Tight junctions are slightly disrupted than that between septal body epithelial cells (Fig. 3). The submucosa of both septal body and inferior turbinate shows a wide range of ultrastructural similarity and inflammatory cell infiltrate (Figs. 4 and 5) and it is noticed that the extracellular matrix of the inferior turbinate shows a more well-arranged collagen fibers than that of the nasal septal body.

Discussion


The swell body, the septal cavernous body, and the septal turbinate have all been used to characterize the nasal septal body in the literature.

Figure 3



Electron micrograph of nasal septal body (right) mucosa showing normal respiratory epithelial cell (EC) with obviously noted intraepithelial goblet cells (G) full with mucus (M) with tight junctions. Electron micrograph showing inferior turbinate mucosa (left) showing oval nucleus (N) in euchromatin pattern, and a great density of mitochondria, less number of cilia (C) implantation in apical surface, tight junctions are slightly disrupted, large number of intraepithelial goblet cells (G) (full with mucus). Scale bar = 2 μ m.

Figure 4



Electron micrograph showing cell of a Bowman's gland in septal body (right) submucosa having irregular nucleus (N), electron-dense cytoplasm (C), and large number of secretory granules. Submucosal glands were more active and full with secretion. Electron micrograph of submucosal glands of the inferior turbinate (left) with irregular nuclei (N) showing huge amounts of mucous and some of them showing exocytosis. Scale bar = 2 μm.

Table 1 Mean area%, SD of collagen fibers deposition in septal body group and IT group compared with paired t-test

	SB group	IT group
Mean area %	13.76	26.58
SD	1.4462	1.3552
P		0.000
Significance (S) at P<0.01		S

SB, septal body.

Table 2 Mean area %, SD of Periodic acid-Schiff positive reaction in septal body group and IT group compared with paired t-test

	SB group	IT group
Mean area %	19.89	7.89
SD	1.5896	1.3298
P		0.000
Significance (S) at P<0.01		S


SB, septal body.

Despite its numerous names, its precise involvement in nasal airway physiology is unknown. Because it is made mostly of expansile vascular tissue, some writers believe it impacts airflow in a way similar to the inferior turbinate [8].

Changes in the volume of these venous sinusoid containing structures in the nasal cavity, particularly at the level of the nasal valve region, which includes the nasal septal body, affect airflow during inspiration and expiration and may lead to nasal obstruction more quickly and frequently than the inferior turbinate [3,9].

This study confirms that the nasal septal body mucosa is rich in seromucinous glands, as reported by Saunders *et al.* [4] and Elwany *et al.* [2], and that this property

Figure 5



Electron micrograph extracellular matrix of nasal septal body (right) showing abundant collagen fibers (CF), plasma cells (P), and fibroblasts (F). Electron micrograph of the extracellular matrix of inferior turbinate showing numerous inflammatory cells and fibroblasts (F) with irregular nucleus (N) and well-arranged collagen fibers (CF). Scale bar = 2 μm.

has important clinical implications because these seromucinous glands are primarily responsible for nasal cavity humidification, and any damage to this region may result in nasal dryness postoperatively.

Using the PAS stain, this study demonstrates that the septal body has less glandular tissue than Wexler *et al.* [10] (49.9%, 7.0) and Elwany *et al.* [2] (59.5%, 6.0), which is higher than the 7.89% (1.32) found in the inferior turbinate.

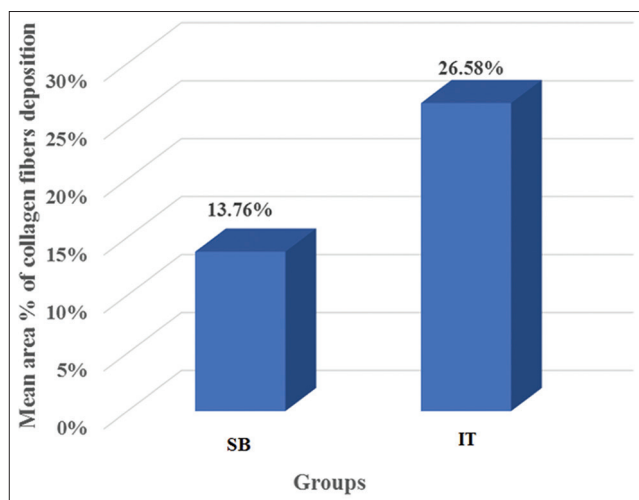
As a result, any plan for reducing the nasal septal body volume to optimize nasal airflow should take into account the glandular tissue's putative protective role in this structure. The presence of glandular tissue in the septal mucosa shows that these tissues are well adapted to endure the drying effects of high airstream impact. As the nasal septal body sends the inspired airstreams toward the turbinates, such a significant effect is expected. If these tissues are unable to endure repeated high-impact airstreams, they will become desiccated, resulting in crusting, disintegration, and epistaxis.

As a result, any consideration of reducing the septal body to improve nasal airflow should take into account the glandular tissue's assumed protective role.

The area fraction given by Berger *et al.* [11] (7.89%, 1.32) is slightly lower than the proportion of inferior turbinate glands we describe (7.89%, 1.32) (11.07%, 5.96) for the inferior turbinate.

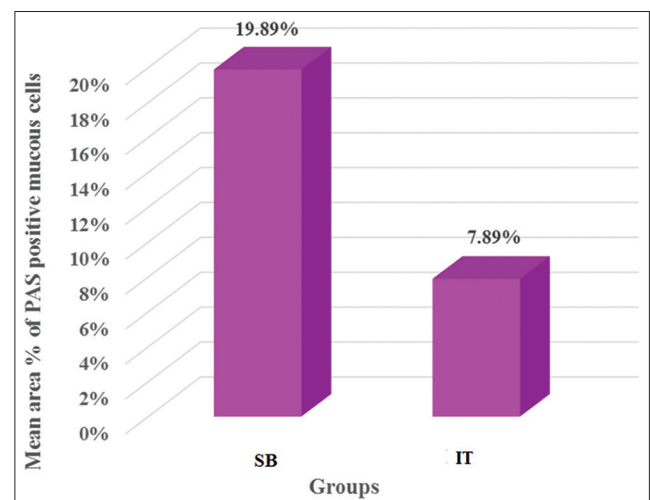
This difference could be due to the fact that they did not disclose a history of rhinorrhea or evidence of other coexisting nasal abnormalities to living individuals undergoing biopsies, as well as the fact that the participants in our study were younger (mean age, 33.5 years) than their controls (mean age, 55 years); four of them were elderly (mean age, 78 years), and

Histogram 1



Mean area % of collagen fibers deposition in SB group and IT group. SB, septal body.

Histogram 2



Mean area % of PAS positive reaction in SB group and IT group. PAS, Periodic acid–Schiff; SB, septal body.

it is known that the percentage of normal ciliated respiratory epithelium declines with age [12].

Although the inferior septal mucosa has glandular and vascular structures similar to those of the septal swell body, it is much thinner, and thus the physiological and resistance effects are much less prominent than in the nasal septal body mucosa. This difference may be purely developmental or perhaps in part a response to local airflow stresses over many years.

The inferior turbinate submucosa has more collagen fibers (26.58%) than the septal body submucosa (13.76%), which may play a function in extracellular matrix structural support.

Tight junctions between epithelial cells of the nasal septal body mucosa are more visible than those between epithelial cells of the inferior turbinate mucosa at the ultrastructure level, providing an intercellular barrier and aiding in the regulation of selective solute movements across the epithelium.

In addition, submucosal mucous gland cells in both the septal body and the inferior turbinate have electron-dense cytoplasm and an abundance of normal mitochondria, indicating that these cells have high secretory functions and abundant secretory granules and apical mucous near the surface, and some cells exhibit exocytosis.

Inflammatory cells (macrophages, neutrophils, eosinophils, and dendritic cells) and fibroblasts with irregular nuclei and collagen fibers are plentiful and well distributed in the extracellular matrix of both the septal body and the inferior turbinate.

We owe it to these structures in the upper airway as a response to a variety of environmental and viral stimuli.

In this study, unilateral biopsies were taken from the nasal septal body and adjacent part of the inferior turbinate (from the side that shows compensatory hypertrophy). We believe that this has no effect on our findings because the side that shows hypertrophy has a two-fold increase in thickness of the inferior turbinate bone (not the subject of our study) and a modest contribution of the mucosal layers to the inferior turbinate hypertrophy with a small contribution of the mucosa. Berger *et al.* [13] verified these findings.

The difference in age among the small number of patients in this investigation constituted a constraint, which could have altered the histology results because all cell properties change with age. The patients were of a wide variety of ages. This could have altered the occurrence of glandular cells, which varies with age. Another limitation of this study is the sample size, which, while small, was comparable to that utilized in the Wexler *et al.* [10] investigations on the histology of the nasal septum swell body (septal turbinate).

The current study was conducted on a very homogeneous sample of patients who met the tight exclusion criteria and are thought to be representative of the nonallergic adult population receiving elective septoplasty with or without inferior turbinate reduction.

This work uses a transmission electron microscope to show the ultrastructure of the nasal septal body and inferior turbinate mucosae and submucosa, which have never been shown in any previous study

focusing on these structures (transmission electron microscopy).

The final limitation of this study was the difficulty of specimen orientation, particularly during ultrastructure studies with an electron microscope. As a result, we were unable to symmetrically study and analyze the height and detailed structure of cilia in both groups, and could only conclude the average number of cilia shafts per epithelial cell between the two groups.

Conclusion

This study confirms the presence of venous sinusoids and abundant seromucinous glands in the nasal septal swell body like the inferior turbinate. This should guide us to surgically reduce the volume of nasal septal body for the treatment of certain nasal airway obstruction cases.

Financial support and sponsorship

Nil.

Conflicts of interest

There are no conflicts of interest.

References

- 1 Costa DJ, Sanford T, Janney C, Cooper M, Sindwani R. Radiographic and anatomic characterization of the nasal septal swell body. *Arch Otolaryngol Head Neck Surg* 2010; 136:1107–1110.
- 2 Elwany S, Salam SA, Soliman A, Medanni A, Talaat E. The septal body revisited. *J Laryngol Otol* 2009; 123:303–308.
- 3 Cole P. Biophysics of nasal airflow. *Am J Rhinol* 2000; 14:245–249.
- 4 Saunders MW, Jones NS, Kbala J, Lowe J. An anatomical, histological and magnetic resonance imaging study of the nasal septum. *Clin Otolaryngol Allied Sci* 1995; 20:434–438.
- 5 Kennedy DW, Zinreich SJ, Kumar AJ, Rosenbaum AE, Johns ME. Physiologic mucosal changes within the nose and ethmoid sinus: Imaging of the nasal cycle by MRI. *Laryngoscope* 1988; 98:928–933.
- 6 Yu MS, Kim JY, Kim BH, Kang SH, Lim DJ. Feasibility of septal body volume reduction for patients with nasal obstruction. *Laryngoscope* 2015; 125:1523–1528.
- 7 San T, Muluk NB, Saylisoy S, Acar M, Cingi C. Nasal septal body and inferior turbinate sizes differ in subjects grouped by sex and age. *Rhinology* 2014; 52:231–237.
- 8 Setlur J, Goyal P. Relationship between septal body size and septal deviation. *Am J Rhinol Allergy* 2011; 25:397–400.
- 9 Marshall AH, Johnston MN, Jones NS. Principles of septal correction. *J Laryngol Otol* 2004; 118:129–134.
- 10 Wexler D, Braverman I, Amar M. Histology of the nasal septal swell body (septal turbinate). *Otolaryngol Head Neck Surg* 2006; 134:596–600.
- 11 Berger G, Balum-Azim M, Ophir D. The normal inferior turbinate: histomorphometric analysis and clinical implications. *Laryngoscope* 2003; 113:1192–1198.
- 12 Schrödter S, Biermann E, Halata Z. Histological evaluation of age-related changes in human respiratory mucosa of the middle turbinate. *Anat Embryol (Berlin)* 2003; 207:19–27.
- 13 Berger G, Hammel I, Berger R, Avraham S, D Ophir D. Histopathology of the inferior turbinate with compensatory hypertrophy in patients with deviated nasal septum. *Laryngoscope* 2000; 110:2100–2105.